

Discussion of and Clinical Guide for:
The treatment of neoplasm, proud flesh and warts with
sanguinarine and related isoquinoline alkaloids

Revised & Extended
3/1/08

Author and Editor: Terrence S. Fox, Ph.D., P.E.

Contributing Authors:

James H. Bailey, DVM

Mark C. Ingram, DVM

Moiria E. Drosdovech, DVM

Alan B. Lippart, DVM

Terrence S. Fox, Ph.D., P.E.

Dale A. Magnusson, DVM

Sarah L. Green, DVM

Andrew A. Peterson, DVM

Cheryl L. Haass, DVM

Margo R. Roman, DVM

Timothy W. Harkness, DVM, BS

Nancy N. Scanlan, DVM

Betsy A. Hershey, DVM, DACVIM

Contents

	Page
Title Page	i
Contents	ii
Introduction	1
The Nature of Neoplasm	1
Historical use of Bloodroot	5
Chemistry	6
A. Bloodroot	6
B. Neoplasene and related compounds	7
Pharmacology	7
Clinical guide	9
A. Neoplasene – topical	11
B. Neoplasene - Oral primary, adjunct or after care	13
C. NeoplaseneX – injectable	14
1. NeoplaseneX with methyl sulfoxide or saline solution	15
2. NeoplaseneX with saline solution	15
Adverse conditions	16
A. Interactions	16
B. Pregnancy	16
C. Toxicology	16
D. Side Effects	16
Case histories	17
1. James H. Bailey, DVM.....	17
2. Moira E. Drosdovech, DVM.....	25
3. Terrence S. Fox, Ph.D., P.E.....	31
4. Sarah L. Green, DVM.....	35
5. Cheryl L. Haass, DVM.....	40
6. Timothy W. Harkness, DVM, BS.....	43
7. Betsy A. Hershey, DVM, DACVIM	51
8. Mark C. Ingram, DVM.....	55
9. Alan B. Lippart, DVM.....	58
10. Dale A. Magnusson, DVM.....	63
11. Andrew A. Peterson, DVM.....	72
12. Margo R. Roman, DVM.....	76
13. Nancy N. Scanlan, DVM.....	80

Contents (cont'd)

Figures

Figure 1 – Sanguinarine.....	6
Figure 2 – Apoptosis and Necrosis – Neoplasm vs. Normal Cells.....	8
Figure 3 – Neoplasene topical (tumor)	11
Figure 4 – Patches – Squamous Cell Carcinoma Photo Chronology.....	19
Figure 5 – Misty - Undifferentiated Sarcoma Treatment Photo Chronology...	21
Figure 6 – Sassy – Unidentified Sarcoma Treatment Photo Chronology.....	23
Figure 7 – Sassy – Healing Up.....	24
Figure 8 – Izzy – Unidentified Growth Treatment Photo Chronology.....	26
Figure 9 – Blue Hulse – Unidentified Growth Treatment Photo Chronology...	29
Figure 10 – Blue Hulse – Unidentified Growth Treatment Photo Chronology.	30
Figure 11 – T. Fox – Mast Cell Tumor that Impaired Hearing.....	32
Figure 12 – T. Fox – Mast Cell Tumor Treatment Photo Chronology.....	33
Figure 13 – T. Fox – Mast Cell Tumor Treatment Photo Chronology.....	34
Figure 14 – Cedar – Soft Tissue Sarcoma Treatment Photo Chronology.....	39
Figure 15 – Kodi – Liposarcoma Treatment Photo Chronology.....	41
Figure 16 – Ben – Mixed Cell Tumor Treatment Photo Chronology.....	43
Figure 17 – Ben – Mixed Cell Tumor Treatment Photo Chronology.....	44
Figure 18 – Rosie – Unidentified Growth Treatment Photo Chronology.....	45
Figure 19 – Rosie – Unidentified Growth Treatment Photo Chronology.....	46
Figure 20 – Flower – Acute Malignant Fibrosarcoma Treatment Photo Chronology.....	47
Figure 21 – Flower – Acute Malignant Fibrosarcoma Treatment Photo Chronology.....	48
Figure 22 – Alex – Papilliferous Cyst–Adenocinoma Treatment Photo Chronology.....	48
Figure 23 – Alex – Papilliferous Cyst–Adenocinoma Treatment Photo Chronology.....	49
Figure 24 – Cowboy – Malignant Melanoma Treatment Photo Chronology....	49
Figure 25 – Cowboy – Malignant Melanoma Treatment Photo Chronology....	50
Figure 26 – Roxie – Nerve Sheath Tumor Treatment Photo Chronology.....	53
Figure 27 – Jasmine – Nerve Sheath Tumor Treatment Photo Chronology.....	54
Figure 28 – Ali – Spindle Cell Carcinoma Treatment Photo Chronology.....	59
Figure 29 – Katie – No Biopsy Tumor Treatment Photo Chronology.....	60
Figure 30 – Max – Unidentified Lump Treatment Photo Chronology.....	61
Figure 31 – Abby – Unidentified Growth Shown After One Treatment and Healing Photo Chronology.....	62

Contents (cont'd)

Figure 32 – Rudolph – The Fractious Feral Feline Treatment Photo Chronology.....	63
Figure 33 – Rudolph – The Fractious Feral Feline Treatment Photo Chronology.....	64
Figure 34 – Quarter Horse Mare – Oral Tumors Treatment Photo Chronology.....	66
Figure 35 – Quarter Horse Mare – Oral Tumors Treatment Photo Chronology.....	67
Figure 36 – Quarter Horse Mare – Oral Tumors Treatment Photo Chronology.....	68
Figure 37 – Quarter Horse Mare – Oral Tumors Treatment Photo Chronology.....	69
Figure 38 – Quarter Horse Mare – Oral Tumors Treatment Photo Chronology.....	70
Figure 39 – Quarter Horse Mare – Oral Tumors Treatment Photo Chronology.....	71
Figure 40 – Dollar – Proud Flesh Treatment Photo Chronology.....	72
Figure 41 – Dollar – Proud Flesh Treatment Photo Chronology.....	73
Figure 42 – Dollar – Proud Flesh Treatment Photo Chronology.....	74
Figure 43 – Dollar – Proud Flesh Treatment Photo Chronology.....	75
Figure 44 – Coco – Bout with Cancer Treatment Photo Chronology.....	78
Figure 45 – Coco – Bout with Cancer Treatment Photo Chronology.....	79

Tables

Table 1 – Neoplasene Oral Dosage	13
--	----

Introduction

This paper is intended to serve as a clinical guide for the use of isoquinoline alkaloids and their salts in the treatment and eradication of fast growing tissue. Bloodroot - *Sanguinaria canadensis* - Neoplasene, and related compounds are the focus of discussion.

Most medical professionals would agree that plant derived penicillin, morphine and aspirin are wonder drugs. There are other powerful botanical drugs that warrant the wonder drug recognition. The alkaloids in *Sanguinaria canadensis* commonly named puccoon or bloodroot are one of the prominent candidates deserving of the wonder drug designation. Whether used as the whole root or fractionated active principals the preferential attack of neoplasm and other rapidly growing tissue including warts, proud flesh, and microbes presents tremendous advantage in the eradication of diseased tissue.

The Nature of Neoplasm

Cancer is broadly thought of as if it is a visually identifiable mass with structural organization and defined observable boundaries (i.e. a tumor). This view, while sometimes accurate is in general not valid. Cancer may be present as a tumor, a field of neoplastic tissue without structural integrity, isolated diseased cells or collections of diseased cells that escape notice. Further the progression of the disease may occur because diseased cells may be carried throughout the body by the circulatory system or entirely new neoplastic cells may develop by the same mechanism that set the stage for the origin of the first cancer to appear.

In a creature there is a continuous process of cell creation by mitosis and cell destruction by apoptosis. Cells may divide about fifty times, on average, before they die of old age. By this process one cell becomes 2 then 4 then 8 until at 50 divisions and subdivisions 10^{15} cells may be created. It is clear that cell destruction must be very active or a creature would surely grow beyond the space and food available. Apoptosis, gene controlled cell suicide, keeps pace admirably when a creature is young, has a strong immune system, is isolated from carcinogens and is shielded from radiation. Apoptosis may degenerate over the lifetime of the individual.

The apoptotic gene may become mutated and dysfunctional to some degree, or even eliminated. If this occurs then tissue which normally would self-destruct and be gathered by macrophages, does not self-destruct. The abnormal cells may be of

any and varied anatomical origin and they may be in multiple locations and may in fact be widespread in the individual. Debilitating or visible and/or palpable tumors may develop locally. It is a hasty mistake to believe that the removal of a tumor is the removal of the neoplastic disease. Tumors may form because of isolated exposure to carcinogens (e.g. vaccine induced fibrosarcoma). Diseased tissue may metastasize from a tumor, but this author (T.S. Fox) believes that usually the diseased cells are already widespread and metastasis from a lesion site is real, but a small part of the spread of the disease.

It is often heard that: “we think we got it all, the margins are clean, the lungs were clear, etc.” Pathologists argue about the tissue samples that they look at under a microscope with benefit of all the cytology aids at their disposal and the expert consultation of their associates. Common verbiage such as undifferentiated, questionable, precancerous, transitional, maybe, pervade their reports. They clearly have not made reliable sense out of biopsy analysis. Using ultrasound or radiographs as tools to determine the presence of cancer are not reliable. They enable visualization of an abnormal lump but they just aren’t up to the task of reliable diagnostics. This author (T.S. Fox) believes that inordinate attention is paid to diagnostics because, until now, little could be done to eliminate neoplastic disease so instead of treatment mainstream protocol has been to study the symptoms a lot and treat the disease a little.

Neoplasm exhibits a multifaceted character that has drawn the attention of researchers who look for its weaknesses in an effort to create a treatment which will eradicate the disease. The many variations exhibited by abnormal cells include: anatomical origin, genetic variations – both cause or disallow apoptosis – influence mitosis, size, growth rate and tumor proximity to or involving critical anatomical organs and systems, is another.

Mainstream oncological protocols available to treat cancer (i.e. alternative or adjunct to surgery) include injury to cells by chemical or irradiation therapy. These protocols generally induce apoptosis by stimulating the tumor suppressor gene. If this gene is absent or altered these cancer cells survive these treatments presenting a major limitation. Further limitations of mainstream protocol are the collateral damage done to normal cells and the inability to cause DNA damage uniformly and sufficient to effect apoptosis or effect necrosis. Therefore, even cells that have a proper viable tumor suppressor gene may escape mortality.

Diagnostics

Typically when cancer is obvious or suspect a biopsy is undertaken to type the

neoplasm and to afford some guidance in treatment. It is accomplished routinely, largely because it is a task that can be accomplished and allegedly allows a more definite outline of treatment protocol. Further, of a positive nature, a discussion between veterinarian and client can be based on diagnostics not just speculation. However, all too often biopsy reports are vague, uncertain or incorrect. Further, once disturbed a biopsied tumor frequently is motivated. The chief non-clinical benefits of biopsy appear to be psychological. The doctor and the animal owner are at least doing something and this alone affords a measure of solace.

It is broadly accepted that when the malignant diagnosis is confirmed by biopsy that the course is set. Diagnostics and treatment are the typical focus, by a series of expensive tests, often unsuccessful attempts at surgical removal, chemotherapy, irradiation and drugs for a host of effects. Cure is held out as a possible but not to be expected outcome.

Treatment

The attending veterinarians treating neoplasm do the very best they can with: clients that bring animals to them late, and too late; clients that will not consent to the expense and risks of treatment options and treatment options that fall short of success. Current oncological approaches are increasingly effective and patients do recover or at least have quality time added to their life.

Surgical removal is compromised and success limited by tumor location, size, invasiveness, identification of tumor boundaries and the existence of neoplasm that is metastasized and small and/or remotely located tumors or diseased pre-malignant tissue that escape notice. Efficacy of chemical and irradiation therapies are limited. They not only damage healthy and nonmalignant tissue they also often fall short of effecting mortal damage to the target cells. Treatment progresses hopefully with success. All of this often leading to failure and the stoic acceptance that all that can be done has now been done and euthanasia or animal suffering is inevitable.

What has been needed is a drug that causes apoptosis or necrosis in all neoplasm and does so preferentially sparing healthy cells. Isoquinoline alkaloids and their salts appear to present just this effect.

Observations: A Different Approach/A New Drug/A Treatment Theory

- A frequently held lay misconception about neoplasm is that there are only two conditions. Namely a tumor is judged benign, therefore great relief is

felt, or it is malignant and the death knell is sounded. In fact there is a continuous process by which healthy normal tissue is invaded with diseased tissue that escapes notice. This neoplastic tissue may progress to become more and more diseased and aggressive. Thus there are an infinite number of states of the diseased tissue. A “benign” tumor is diseased but just not as diseased and hostile as it may become.

- It has been observed, that a tumor that exhibits structure, with a discernable shape and boundaries is in fact surrounded by tissue that appears normal by visual inspection. This diseased tumor is sometimes judged pre-cancerous or questionable on biopsy and sometimes this diseased tissue escapes notice by the pathologist. This tissue likely is diseased but not so far advanced in state as to be readily recognized.
- Whether tumors arise from connective tissue, melanocyte, fibroblast, basal cell, squamous, epithelial, mast cell, or any other anatomical origination site they do have in common that they are abnormal and usually rapidly growing. They are characterized by a cell membrane that apparently is different from normal cell membranes or is different just because it is not fully developed. Either way the neoplastic cells are vulnerable as a result of this characteristic whether they are “benign” or “malignant” or whether they are prostate, mammary, melanoma or any other type. Therefore biopsy is an unnecessary procedure with the new approach because little useful information is resultant from biopsy.
- Often a reappearance of an excised tumor is referred to as a “regrowth” when in fact a new tumor has simply developed in the neighborhood from the diseased tissue that has escaped visual or biopsy detection. The practice of removing a margin around an excised tumor removes a portion of this field of diseased tissue. The closer to the active structured tumor the more actively diseased this field is typically observed to be. The field, just as the flagrantly malignant structured tumor, has a different mix of polysaccharides in the immature cell membrane which also lends it vulnerable.
- Malignant neoplasm is characterized by the absence of genetic mortality – the malignant cells do not succumb to apoptosis. There is a blockage by the unique synthesis of an apoptosis blocking enzyme in some aggressive tumors. Other mechanisms of cell longevity may be the absence of tumor suppressor genes in the DNA that initiate apoptosis. In addition, neoplasm is largely invisible as far as the immune system is concerned. The neoplasm

is also invisible, in large part, to the host and to the eye of the oncologist until it is advanced. By the time the cancer is obvious it may be too late for effective excision, chemotherapy and irradiation or growth inhibitory drugs to be of value other than to stave off for awhile the inevitable.

- There are some worthy chemicals that do “recognize” neoplasm preferentially. The viscotoxins in mistletoe are moderately effective. Benzyl isoquinoline alkaloids are however stunning. These alkaloids clearly attack neoplasm preferentially and this fact has been known and largely ignored by pharmaceutical researchers for nearly two hundred years.
- There have been barriers to the development and use of really effective cure oriented chemical treatment of neoplasm which are intertwined with political, economic and regulatory realities. Cancer treatment and research are big business. Tremendous resources of facilities, personnel and funding are allocated to address education, equipment, real estate, personnel and patented designer drugs. Big organizations have momentum; they do not change direction easily or quickly.
- It has been viewed by drug developers that patentability may not be attained on some phytopharmaceuticals. Economic barriers are created because of the huge cost of gaining FDA approval of drugs and the need to recover these costs. Thus regulatory requirements simply preclude their development. No institution wants to develop a treatment that works while simultaneously putting them in bankruptcy.

A new drug shows promise

The FDA’s policy of letting veterinarians decide what works and what doesn’t has led to the veterinary use of sanguinarine and related alkaloids, which while under the regulatory authority of the FDA are not required, at this time, to undergo usual procedure and approval.

I would believe that the chemistry extracted from *Sanguinaria canadensis* is patentable, or if not the exact processing to produce the highly effective drugs Neoplasene and NeoplaseneX can be patented or kept as trade secrets. Our intent is to keep the intellectual property as a trade secret.

Historical use of Bloodroot

The botanical *Sanguinaria canadensis* is native to North America from just west of the Missouri river to the Atlantic Coast and from the southern states north into

Canada. It has been used by Native Americans for unknown generations prior to the arrival of European explorers and colonists. The principle medicinal use included use as an antimicrobial, although it is doubtful that this effect was well understood. It was also used as a treatment for tumors and warts. More recently sanguinarine, an active principle in bloodroot, was used as a dentifrice. Preparations derived from bloodroot as cancer treatment abound and have been referred to as escharotics and other incorrect or less descriptive terms. It is clear that the mechanism of action is not as a caustic. Bloodroot chemicals and Neoplasene are simply not escharotic. They do not burn flesh.

The dried and pulverized root (i.e. powder) has been mixed with many extract solvents and used topically and orally. When used alone an extract of bloodroot attacks neoplasm readily. The necrotic tissue seals, at least in part, the attacked surface of the tumor and arrests the progress of tumor destruction. To get around the problem of sealing off the tumor, salt compounds of many kinds were found to be helpful. One such salt has been zinc chloride, which is caustic. The misnaming of some bloodroot based medicines as escharotic is encouraged by inclusion of zinc chloride in their preparation. Some may be escharotics because of the way they are formulated. In a few of these lay preparations the zinc chloride is oxidized to many ionic species. The resultant salve is acidic and cancer cells are eliminated by apoptosis and necrosis upon contact as a function of concentration and exposure time.

Chemistry

A. Sanguinarine

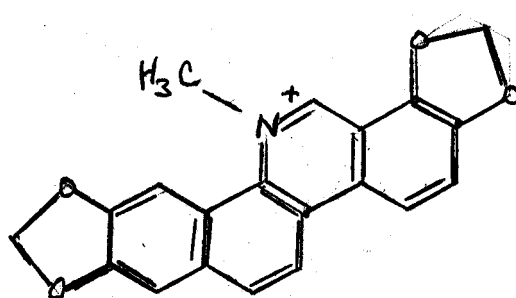


Figure 1

Alkaloids present in abundance in the root of *Sanguinaria canadensis* include the isoquinoline alkaloids sanguidimerine, sanguinarine, chelerythrine and protopine. Many others are also present, including dihydrosanguilutine and macarpine.

There are profiles of the chemistry of bloodroot obtained by chromatography, mass spectroscopy and several other analytic techniques. There are numerous papers on the chemistry and pharmacology of bloodroot and its active principles that focus on anti-microbial and anti-plaque efficacy. What is lacking is substantial research connecting the mechanism of action between bloodroot, its constituent chemicals and apoptosis, necrosis and inhibition of proliferation of neoplasm. Only one paper has been found which sets forth, rather clearly, the affinity of sanguinarine to attack cancer cells preferentially.

B. Neoplasene and related compounds.

It is not appropriate to think of or refer to Neoplasene as bloodroot. It is no more bloodroot than stainless steel is rock. Further, Neoplasene is not black salve. Black salves have been around for a very long time. They are quite varied mixtures and compounds. Neoplasene is made up of a particular set of chemicals extracted from, in part, the bloodroot plant.

Menstrum is the medium used to extract the active chemicals from any botanical. The menstrum used for Neoplasene is a collection of halogen species. The menstrum is slightly acidic because of protic acid content. The plentiful isoquinoline alkaloids sanguinarine, sanguidimerine, chelerythrine, protopine and others are chemically modified and figure into the observed enhanced efficacy of Neoplasene over previously formulated medicines based upon the chemicals in bloodroot.

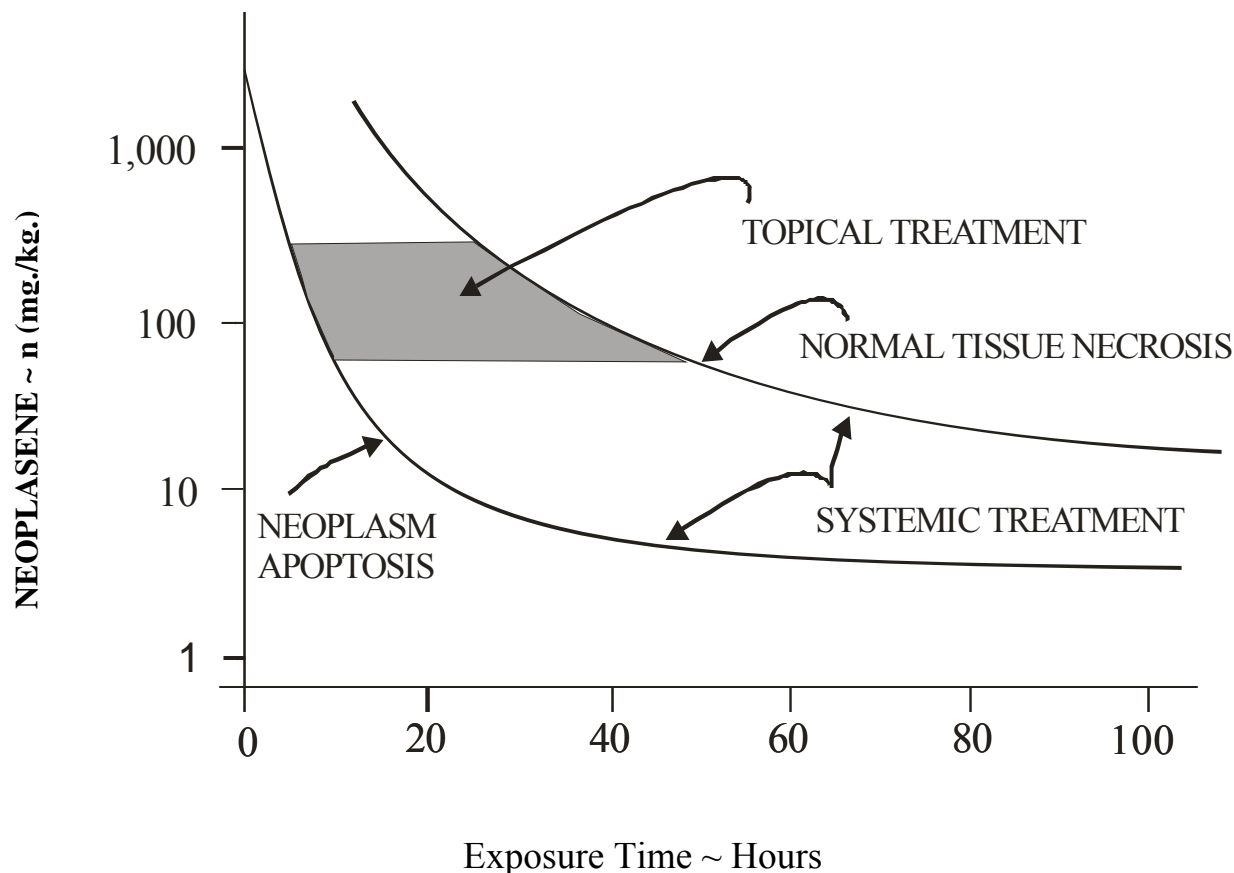
Because the menstrum is so powerfully ionic it is believed that much more of the alkaloid content is extracted and given molecular mobility and therefore more bioavailability than bloodroot alone or bloodroot in traditional alcohol/water menstrum or in most other bloodroot products available. What is certainly known is that the efficacy of so called black salves that use ZnCl_2 or an other salt in the formulation are more aggressively active than those that don't contain ZnCl_2 in combating neoplasm.

Pharmacology theory

The active principles interact with DNA. It also inhibits adenosine triphosphatase. These and other mechanisms offer clues to the - how does it work on neoplasm – questions. Sanguinarine also potently inhibits nuclear transcription factor NF- κ B. This is a key mechanism of Neoplasenes affinity to cause apoptosis.

There is a functional relationship between the death of neoplastic cells and exposure to Neoplasene. We know that the apoptosis and necrosis resulting in the

death of diseased cells is directly proportional to the concentration of the active principles and to the exposure time to Neoplasene, figure 2. Figure 2, while more than qualitative, should be interpreted with caution. There are very little data on which it is based. It is qualitatively accurate but quantitatively approximate.



APOPTOSIS and NECROSIS – NEOPLASM & NORMAL CELLS*

*This figure is quantitatively approximate. Do not rely on the numerical values.

Figure 2

The cell membrane is the armor that protects the cell from attack. However, the neoplastic cell is observed to be vulnerable. There is reason to believe that bloodroot like mistletoe contains toxic lectins that selectively bind to the cell membrane sugars peculiar to fast multiplying neoplasm and this renders the cell membrane of neoplasm transparent to, at least, sanguinarine among the cytotoxic isoquinoline alkaloids of bloodroot. Healthy cells possess a cell membrane that is opaque to attack unless dosage or exposure time is high, then attack results in necrosis not apoptosis. Apoptosis and necrosis of cancer cells is accomplished at

lower doses of sanguinarine than normal cells. By adjusting concentration and exposure time neoplasm is condemned and normal cells are spared.

Sanguinarine, in micro-molar concentrations preferentially eliminates cancer cells by apoptosis without precipitating the death of normal cells. The dosages necessary to cause the death of cancer cells is in the low micro-molar range beginning at 600 nano-molar concentrations in laboratory tests (Ahmad et. al. Journal of Clinical Cancer Research, April 2000). Regardless of the source of the zinc ion its presence catalyzes genetic and transduction pathways accelerating the demise of cancer cells and potentiating apoptosis.

The active principles are emetic and will induce G.I. distress if the concentration is too high or the residence time is too great. It has been found that if the drug is administered during a meal that the recommended dosages (table one) are beneath the threshold of G.I. distress. The stomach contents sufficiently dilute the Neoplasene so that it gets into the bloodstream before it attacks the G.I. tract lining. There it is further diluted and circulates throughout the body causing apoptosis and necrosis of neoplasm wherever it contacts diseased cells.

When neoplasm is attacked there is localized inflammation and soreness because the immune system is kick started. Normal bodily processes that eliminate necrotic cells will not have trouble ridding the system of the dead cancer cells because the increase in load over normal bodily processing is very small due to the dose controlled slow rate of apoptosis and necrosis.

The elevated activity of Neoplasene is believed to be due to the deliberate elevation of ionization. Also plant lectins are believed to play a role in potentiating cell membrane transparency. This process is ill understood but may be activated by the presence of the powerfully ionic menstrum. Further the probable chemical modification of constituent alkaloids to alkaloid salts in bloodroot may favorably contribute to the strong preferential attack of neoplasm by Neoplasene.

Clinical guide – General protocol – See the Appendix for a more detailed strategy and more specific detail.

For this discussion benign is defined as abnormal but possessed of an imbalance between mitosis and apoptosis. Malignant is an imbalance strongly in favor of mitosis including the condition where the gene initiating apoptosis is absent or compromised by mutation and the situation where a tumor suppressor gene is absent or compromised. Cure is the desirable situation where the imbalance is in favor of apoptosis.

There exists well documented in-vitro evidence that sanguinarine preferentially attacks neoplasm at dosage and exposure times less than that required to cause cytotoxic necrosis of normal cells. A large body of in-vivo success evidence the clinical efficacy of sanguinarine and related alkaloids to do the same. There are some lessons to be learned from our growing body of case histories.

1. Tumors sometimes grow back after treatment with Neoplasene.
 - a) Debriding (i.e. forcing necrotic tissue to disengage) increases the occurrence of reappearance.
 - b) Cessation of treatment after an obvious lesion has been removed may leave diseased tissue behind to develop into a new tumor that may be mistaken for regrowth.
 - c) Before cancer has developed conditions presented that led to its origin. Even if all neoplasm has been eradicated cancer may reappear for a second or more times as the original cause may instigate reappearance which may be mistaken for regrowth.
2. Oral after care has resulted in greatly reduced incidence of reappearance of cancer.
 - a) Once the cancerous mass has been debulked by excision, apoptosis, necrosis, irradiation, injection or any other means the rate of growth of residual (or new) neoplasm is likely less than the cell mortality rate of the dose limited* oral application (*see page 13 and the Appendix).
 - b) Oral administration is systemic in its effect. Thus cancer remote and unseen is attacked.
 - c) Periodic prophylactic use of oral administration eliminates neoplasm if it is slow growing or of a small bulk even if it is rapidly growing.
3. Smearing or drenching margins with Neoplasene or NeoplaseneX is helpful.

Treatment

The task is to get enough of the active chemical(s) in contact with the neoplasm for sufficient time to cause the death of the diseased tissue without causing necrosis of healthy tissue. Further the cancer must be destroyed faster than it is growing, slower than the rate at which macrophages, or sloughing, can eliminate it and simultaneously anorexia must be avoided. There are several means by which apoptosis and necrosis may be induced by the use of Neoplasene and NeoplaseneX. These, at present, include: ointment, injectable liquid and oral protocols. It is recommended to routinely administer astragalus extract concurrent with any Neoplasene compound treatment to keep the immune system roaring except in the case of lymphoma where an overactive immune system is part of the problem.

Which, or which ones of these, are used depends largely upon the location, size and shape but not upon the pathological type of cancer involved. Treatment protocol has been found to be largely independent of cell type.

Many presented tumors cannot be excised because of the age of the patient, rendering it risky to anesthetize. Further, many pet owners cannot, or will not, afford the high cost of surgery, chemotherapy, irradiation and prescription drugs and would opt for euthanasia or needless suffering. Neoplasene compounds offer a less expensive protocol.

Cancers that are near the exterior of the body are accessible and therefore easily treated by:

1. topical application directly on the tumor.
2. injection in and around the tumor.
3. oral adjunct, primary or after care.

Neoplasene – topical

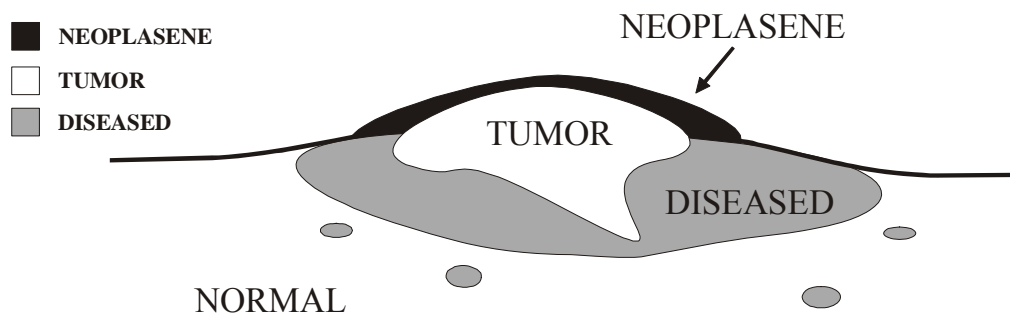


Figure 3

Neoplasene can be applied directly to the visible tumor as shown (figure 3). It is common to have a tumor with sufficient structure to visibly discern its boundaries. It is also common to not be able to visually detect the limits. Often there is diseased tissue which is not an organized tumor around and near such a carcinoma.

Clip off hair, if any, on and around the tumor. It is usually not necessary but may be helpful to prick around the affected area with a needle. This opens up any healthy or semi-healthy skin facilitating treatment.

Apply (i.e. dab on) a sufficient amount of Neoplasene to cover the affected area so you cannot see through it. Use only enough to obfuscate the target area. About one to two mm thickness is usually sufficient. Use an E collar!

If it dries out the constituent alkaloids are immobilized and their bioavailability is limited. Further, dehydrated necrotic tissue shrinks and causes discomfort.

Caution: Neoplasene will strongly react with diseased tissue. Expect some scarring. If the tumor is extensive, non-protruding and the Neoplasene is spread widely a large wound will have to be managed. Therefore treat a small sized area initially and continue treating a small area at a time.

If cancer or a virus is present there will be a mild burning sensation upon application and a scab will begin to form. If there is no diseased tissue, there will be no significant effect. Leave the Compound on for twelve (12) hours. If the tumor is large and protrudes prominently from the body it is indicated to cover the entire tumor and leave on or reapply until the tumor is gone. This is appropriate since prolonged contact with normal tissue is avoided in this situation. If the tumor is protruding and its boundaries are clear, continued treatment daily until it sloughs is appropriate. Otherwise, stop after the first or second twelve hours and let the dead tissue separate and fall away.

After twelve hours wash gently with soap and water and rinse the treated area thoroughly with three percent hydrogen peroxide. If the Neoplasene has penetrated the skin, there will be a red ring around the area, and the tissues will be grayish white. The immune system will be awakened and swelling and soreness will present.

If only a small area of the treated area is grayish white or red and swollen, then you can apply an additional amount of Neoplasene and repeat the process for an additional twelve (12) hour period. Clean the area and rinse with 3% hydrogen peroxide. Do not apply more salve at this point.

DO NOT LET A HARD SCAB FORM. Keep it soft with Buck Mountain Wound Balm. Twice or thrice a day, clean around the edges of the affected area. Cover liberally with fresh Balm.

In two to ten days the necrotic tissue will slough off. Examine to determine if the tumor is still in part present. If so, repeat the procedure.

DO NOT FORCE THE NECROTIC TISSUE OFF. Let it detach without any help other than gentle cleaning with a three percent hydrogen peroxide soaked cotton swab. If the tumor, or part thereof, detaches in two to five days there likely is no more tumor present in the detached area. If it takes six or more days to detach there likely is more tumor present and a repeat application is indicated. The boundary between dead tumor and healthy tissue is well defined hence necrolysis

is quick (i.e. two to five days). The boundary between dead tumor and live tumor is not well defined and is tenacious, thus six days or longer to separate is common.

Expect a wound to manage. Its size will be in proportion to the extent of the tumor and the amount of Neoplasene compound applied. Scarring may be minimized by use of Buck Mountain Wound Balm to keep the wound moist and encourage healing. When you feel you are done, a repeat light treatment may be helpful to assure complete demise of diseased tissue. It is preferred to use oral adjunct and oral after care to repeat topical salve applications.

If the Neoplasene becomes dry in the container, add distilled water to moisten. Buck Mountain Neoplasene is somewhat acidic. However, it can be handled with bare fingers without difficulty.

Neoplasene - Oral primary, adjunct or aftercare – See the expanded sections in the Appendix for further Oral protocol information.

Start with the dosages of table 1 and double the dose over a few weeks. Use an antiemetic if it is necessary. Metoclopramide HCl has proven to be effective. Oral Neoplasene is very effective. Mixing Neoplasene with meals has proven practical. See the detailed protocol in the Appendix.

	Dose mg.	Strength	Dose cc b.i.d.
Large Herbivore 1,200 pounds	3,900	Neoplasene 1300 mg./cc.	3.00
Large Canine 150 pounds	750	Neoplasene 300 300 mg./cc.	2.50
Medium Canine 80 pounds	400	Neoplasene 300 300 mg./cc.	1.35
Small Canine 40 pounds	200	Neoplasene 300 300 mg./cc.	0.67
Cats & Small Creatures 10 pounds	50	Neoplasene 75 75 mg./cc.	0.67

Note: these are high aftercare doses. See Appendix for details specific to particular protocols.

Neoplasene Oral Dosage for Adjunct or Aftercare

Table 1

Neoplasene and NeoplaseneX can be easily administered. It also can be orally administered as a primary, adjunct or after treatment. In this protocol the objective is to ingest sufficient Neoplasene to kill the neoplasm faster than it is growing while not exceeding that dose which may cause distress.

Capsules of Neoplasene are easy, if somewhat inconvenient, to prepare. The inconvenience is that the Neoplasene will dissolve the capsule. They only last about fifteen minutes. Therefore, they must be filled as they are utilized. This author (T.S. Fox) likes capsules for canines for doses less than 11 mg/kg. and administration with food per the protocols in the appendix for all other doses and patients.

Based on experience about five milligrams per pound of body weight b.i.d., taken with a meal is near the threshold of G.I. distress. Use of three to five milligrams per pound of body weight b.i.d. with (i.e. in the middle of) meals is recommended for adjunct care. This dosage when mixed with a full meal is low enough to not usually upset the G.I. tract in the time before it gets into the blood stream. Once in the bloodstream it is further diluted. It circulates throughout the body attacking neoplasm where it finds it. If the patient becomes anorexic or nauseous an antiemetic may be indicated. Neoplastic cells made lifeless by the recommended oral doses occur at a rate lower than the body's ability to discard dead cells by normal bodily elimination function.

If the cancer is so widespread or growing so fast as to add neoplastic cells faster than apoptosis or necrosis can eliminate it, other means may be required such as surgical debulking or intralesion or intravenous administration of NeoplaseneX.

NeoplaseneX – injectable – See the Appendix for further information on injection of NeoplaseneX.

The injectable forms of NeoplaseneX are extended and filtered alkaloids extracted with a highly ionic menstrum. The menstrum is extended with methyl sulfoxide and alternatively with sterile saline solution.

1. NeoplaseneX with methyl sulfoxide or saline solution

This drug is easily injected in and around a tumor. A workable protocol includes estimating the volume of the active tumor. The desired dose may be diluted with lactated ringers, saline or other suitable solution. Dosage levels increase or not as success may indicate. Intravenous injections at dosages above twelve milligrams per pound of body weight (i.e. twenty-six milligrams per kilogram) should be done

slowly to avoid anaphylaxis. Spreading the dose out over thirty to sixty minutes provides less stress for the patient. Use a quantity of injectable NeoplaseneX equal to ten percent of the estimated tumor volume and injecting it as uniformly as you can in numerous locations in and around the tumor. Do not exceed 25 milligrams per pound of body weight intralesion or 12 mg. per pound of body weight intravenous.

Once the process of apoptosis and necrosis have commenced the immune system will be fired up. Significant inflammation and associated discomfort will accompany this process. A strong immune system is a good thing and nothing should be done to reduce inflammation as the immune system will evict the dead tissue and accelerate healing. If the patient does not have a strong immune response it is, as always, recommended that astragalus be administered (2.0 ml. per 100 lbs. t.i.d.) before, during and after treatment.

2. NeoplaseneX with saline solution (See the Appendix for bladder, prostate and udder infusion).

For higher daily doses without G.I. distress NeoplaseneX with saline can be injected intravenously* or into soft tissue daily. Intravenous injection is an option which I seldom recommend, except for lymphoma and other widespread cancers. The target dosage starts at ten to twelve milligrams per pound of body weight. Therefore, the veterinarian may wish to further dilute the drug with saline solution to adjust the drug to a desired dose. Do not exceed twelve milligrams per pound of body weight under usual circumstances. Build the dose over time until the emetic effect of NeoplaseneX becomes intolerable.

For patients with fast growing inoperable tumors oral administration at high doses is an alternative choice.** It can be administered in doses that cause apoptosis and necrosis of neoplastic cells as fast as the body can eliminate the dead tissue.

Adverse conditions

Interactions - None well documented.

Pregnancy - There is documented emmenagogue and uterine stimulant action. Avoid use during pregnancy. Avoid pregnancy during cancer treatment.

* I recommend oral instead of intravenous injection.

** Oral is simpler, avoids anaphylaxis and up to three times more medicine can be administered to the patient than by IV.

Toxicology - LD 50 – 1,500 to 1,700 mg/kg. There is no reason to be concerned at recommended dosages.

Side Effects – Nausea, immune reaction to the drug is normally modest at recommended dosage. None others observed.

CASE HISTORIES

James H. Bailey, DVM
Associated Veterinary Service
Great Falls, MT

Case #1: Patches a neutered male feline DMH, fourteen pounds, ten years old was referred on April 13, 2004, referred for non-healing lesion on right nostril one cm in diameter. The lesion was previously diagnosed as a scratch or bite and abscess. The lesion was evaluated with four, two millimeter punch biopsy by Vet Path Services, Dr. Hoffman of Scottsdale, AZ. The tissue was identified as a squamous cell carcinoma.

The lesion involved the right nares extending posterior into the nasal cavity. The owner vetoed surgical removal. Neoplasene was offered as an option and the owner agreed.

On April 26, 2004, Patches was anesthetized and maintained with Isoflorane. The area was clipped and cleansed. Buck Mountain Herbal Gold Would Balm was applied around the periphery of the lesion. The lesion was wiped with gauze and a thin layer of Neoplasene was applied to the entire area. Patches was maintained on Isoflorane for thirty minutes and allowed to recover. An E-collar was left on for twenty-four hours. Patches did not appear to be uncomfortable and the E-collar was removed. The lesion was reevaluated on April 27, 2004. The lesion was gray and dry. A small amount of Wound Balm was applied to keep the lesion soft.

On May 3, 2004 the lesion was gray and dry. It was retreated with a thin layer of Neoplasene under Isoflorane anesthesia. On May 6, 2004, the owner reported fluid drainage from the nostril with frequent sneezing. The lesion appeared larger to the owner. Clinical exam revealed heavy scab and tissue separation in the middle of the mass. On May 13, 2004, the lesion was retreated under Isoflorane anesthesia. The Neoplasene salve was applied to an area of normal looking healing tissue. The E-collar was removed after twenty-four hours. May 25, 2004, a normal healing lesion.

On June 15, 2004 there were two small areas of raw tissue in the depth of the lesion. It was covered with Neoplasene under Isoflorane anesthesia. Patches

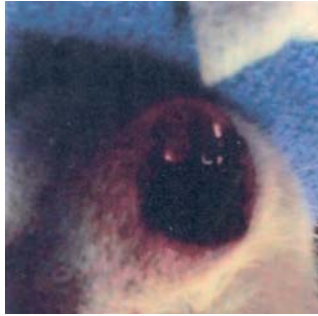
experienced excessive salivation after recovery that resolved in thirty minutes without treatment. On July 2, 2004 we evaluated and retreated the one-two millimeter raw appearing areas with the salve without anesthesia.

On August 2, 2004 there was a fine line of raw appearing tissue deep into the nares. We retreated with Neoplasene under Isoflorane anesthesia. On September 13, 2004 no active lesion could be seen and Patches was acting normal. On October 10, 2004 owner called and reported some nasal discharge and excess sneezing. Patches was examined under general anesthesia. No areas of visible tumor could be seen but a thin red line deep in the nares was treated with Neoplasene. After three hours the Sarcoma Salve was wiped away. No area of reactivity could be seen (previously when the salve was applied within thirty – sixty minutes the tissue would have a gray coloration). Nasal discharge was attributed to exposed nasal mucosa.

On November 18, 2004; March 10, 2005 and July 27, 2005 the tumor bed area appeared normal and no treatment was warranted. On August 23, 2005 bloody mucous discharge was reported by the owner. There was no active lesion. One week later Patches was normal. The cause for the bloody nose was not identified. On September 25, 2005, Patches was a normal, happy cat and the owner was very pleased.

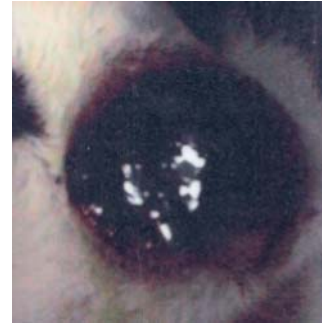Summary: This was a protocol dictated by response to the treatment. General anesthesia was used because of the location of the lesion and the cat's own ability to do damage with its front claws. At no time during or after the treatment did Patches appear to be uncomfortable or in pain. The response of the tumor to the Neoplasene – a/k/a – Sarcoma Salve was dramatic in that minimal tissue was destroyed which would have been impossible with a surgical approach. Normal tissue does not appear to be affected by the Neoplasene. This ability to spare normal tissue is a great asset.

4/26/04



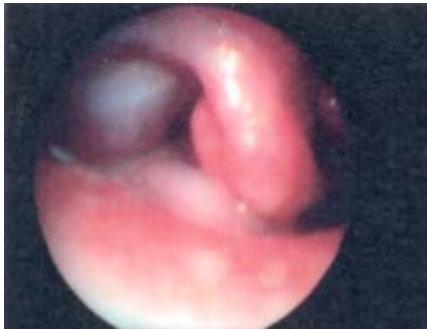Before Treatment

4/26/04

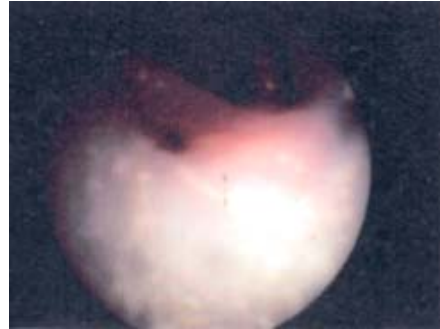


After Treatment

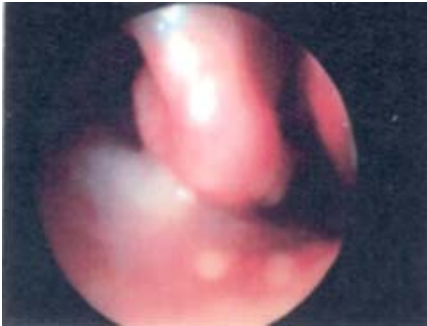
10/11/04



10/11/04




10/11/04



No visible tumor

3/10/05



Healthy cat

Patches - Squamous Cell Carcinoma Photo Chronology

Figure 4

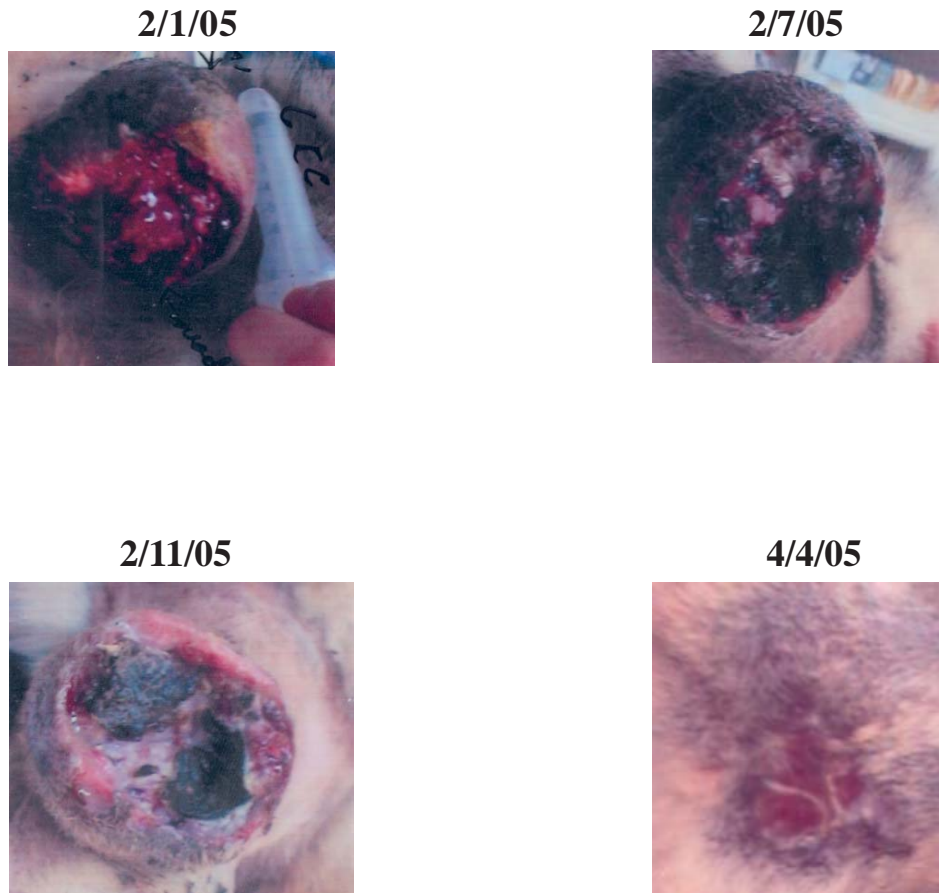
Case #2: January 13, 2005, Misty, a fourteen year old spayed female Elkhound cross, was presented for exam of a “large lump” on the left elbow. This mass was eight – ten centimeter in diameter nearly all the way around covering the anterior, lateral and posterior aspect of the left elbow. Needle aspirate was sent to Montana Diagnostic Laboratory and diagnosed as an undifferentiated sarcoma.

On January 21, 2005 a blood screen performed was unremarkable. Radiographs of the thorax did not reveal any masses or indication of metastasis. On January 25, 2005 the general area of the left elbow was clipped and cleaned with Technicare scrub. A one inch diameter area of Neoplasene was applied to the normal appearing skin on the top of the mass and covered with a bandage. A Rimadyl 120 mg injection was given for pain control and arthritis relief. On January 26, 2005 the bandage was changed. The tumor felt inflamed with blanched skin where the Neoplasene was applied. The same one inch diameter area was retreated with Neoplasene and bandaged. The Rimadyl was continued for arthritis and pain control. The area under treatment did not appear to be painful. On January 30, 2005 the tumor broke open leaving a large open area of necrotic tissue. We reapplied the salve and covered the area with a bandage.

On February 1, 2005 a large amount of necrotic tissue was debrided. The area was retreated with Neoplasene and bandaged. The same treatment was performed on the 2nd and 4th of February 2005. On February 7, 2005 the area was retreated with Neoplasene salve and forty-fifty percent of the tumor was gone, leaving an open, non-painful wound. On February 8th, 11th, 16th and 17th, 2005 the area was cleaned and retreated with Neoplasene. No bandages were applied at these times. On April 4, 2005 there was a one centimeter open non-healed area in the middle of the tumor site. No further treatment was warranted at that time. As of February 8, 2006 the leg has healed and there has been no re-occurrence of the tumor.

Summary: In retrospect, once a week treatment would probably have been adequate. Misty never appeared to be uncomfortable during the three months of treatment. Rimadyl was continued for hip and back pain but undoubtedly aided in pain caused by the tumor. The owner was pleased with the outcome and Misty is doing well. During the active phase of treatment this was an ugly wound so bandaging was more for aesthetic reasons than anything else. Both of these cases would have been difficult surgical problems because of the recommended surgical

margin and scarcity of available skin to close the wounds. Surgically removing these tumors would have resulted in the necessary healing of the wounds by second intention. The ability of the Neoplasene salve to kill cancer and not damage normal adjacent tissue is truly amazing.



Misty - Undifferentiated Sarcoma Treatment Photo Chronology

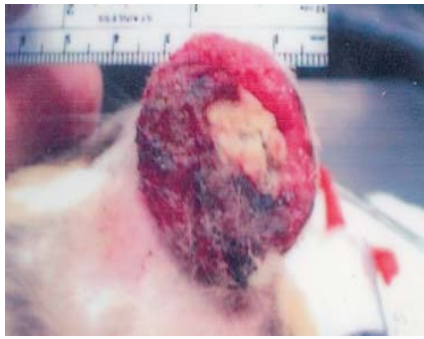
Figure 5

Case #3: December 24, 2004, Sassy Peterson, a sixteen year old calico spayed female cat was examined for a growth on her chin. This growth had been present for four-six months. Clinical diagnosis was squamous cell tumor with tissue necrosis. The lesion was almost three and one-half centimeters in diameter with a necrotic core. The owner declined a biopsy and histopathology.

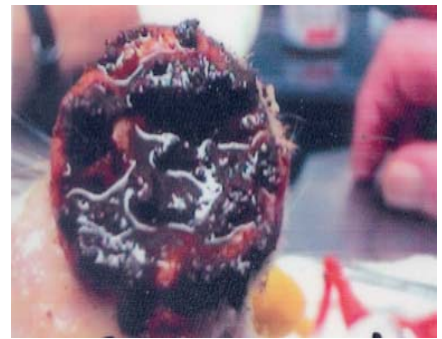On December 29, 2004, Sassy was anesthetized with Isoflurane, masked down followed by intubation. The lesion was clipped and cleaned. A biopsy was taken and sent to the Montana State Diagnostic Laboratory for evaluation. The diagnosis was squamous cell sarcoma. Wound Balm ointment was applied around the lesion and Neoplasene applied directly on the lesion at that time.

On January 7, 2005, the mass had reduced to less than two centimeters in diameter with healthy looking granulation tissue. The cat was sedated with Isoflurane anesthesia and the area was retreated using Sarcoma Salve #1 a/k/a Neoplasene.

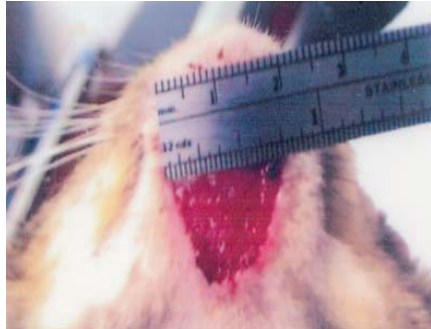
Sassy was to be treated every week, but due to owner non-compliance that schedule was not followed. The following dates indicate when Sassy was retreated January 17, 2005 and January 24, 2005. The tumor was reduced by over 50% in one month and retreated February 11, 2005. February 16, 2005 – the tumor had spread between the mandibles and was retreated. On March 18, 2005, the lesion was healed and looked normal.



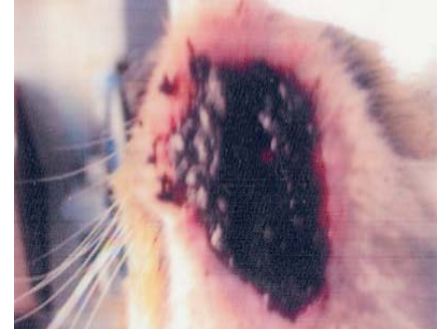12/29/04 pre-treatment



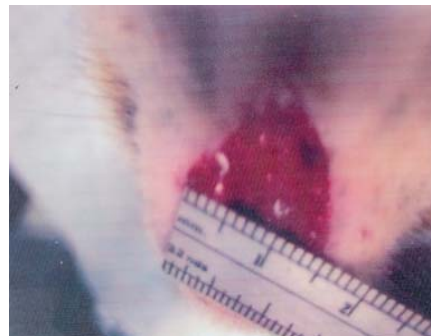
12/29/04 post treatment



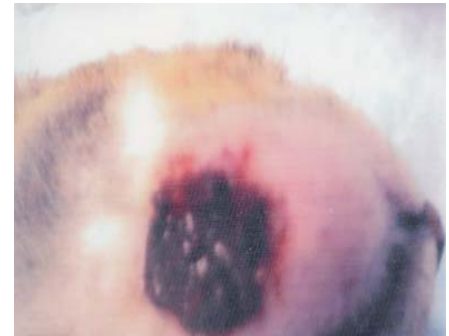1/7/05 pre-treatment



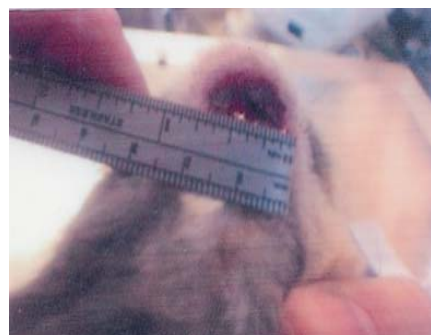
1/7/05 post treatment



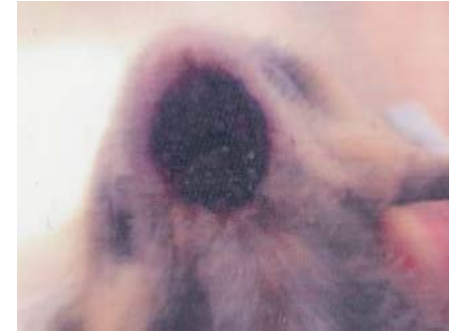1/17/05 pre-treatment



1/17/05 post treatment

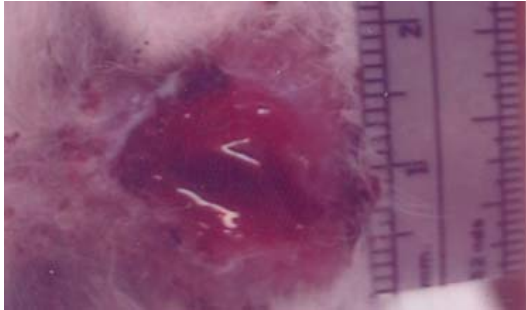


1/24/05 pre-treatment

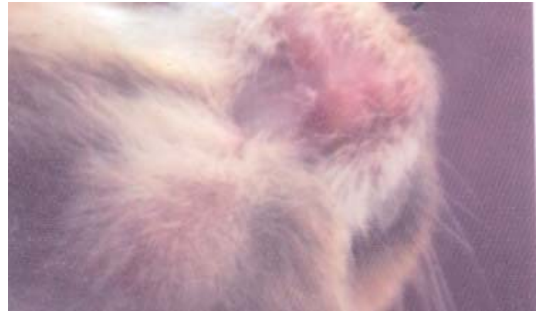

1/24/05 post treatment

**Sassy - Unidentified Sarcoma Treatment Photo Chronology
Figure 6**



2/11/05



3/19/05 - No open lesion

Sassy - Healing Up

Figure 7

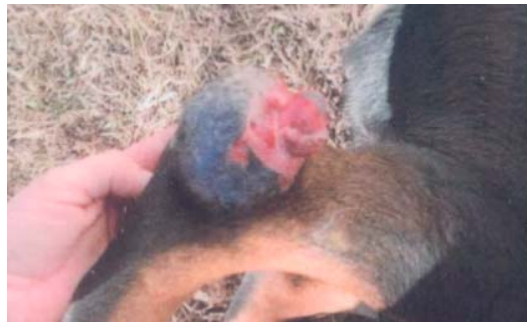CASE HISTORIES

Moira E. Drosdovech, DVM
Pawsitive Veterinary Care
Kelowna, BC

Case #1: Lucky Lindy is a male neutered Yellow Labrador Retriever DOB March 1994 that first came to me in early December 2004 with a growth between his second and third digit of the left front paw. At the time of presentation, it was smooth, firm and non-painful and did not encompass more than the webbing between the toes. No treatment was initiated at that time. However, it grew quickly and by late December, was much larger and was interfering with his gait. Surgery was performed on January 5, 2005 and it was necessary to amputate the second digit to the metacarpal-P1 joint with some growth being left behind due to the extensiveness of the surgery. Histology confirmed fibrosarcoma with intermediate grade malignancy. Recurrence is common with these tumors as it is often difficult to identify all margins of the neoplasm and effect its complete removal. Within two weeks of surgery, further tumor growth was evident and a lump was removed with local anesthetic only. However, another lump took its place, causing a significant lameness, and at this point, when the regrowth was about a two inch diameter, the Neoplasene was started. His first application was March 2, 2005 and by March 9th, the lump was fifty percent reduced in size. By fourteen days following the first application, the tumor was almost completely gone, leaving a raw opening on the medial aspect of the third digit and a defect in between pads on the metacarpal pad. At one month, the areas mentioned were almost completely healed and he was walking very well. To date (April 2006), there has been no recurrence.

Case #2: Izzy Laplante was a ten and one-half year old female Rottweiler with a large growth protruding from her right hock that, at the time of original examination on October 25, 2004, was approximately two and one-half to three inches diameter. Neoplasene was suggested, but declined by the owner until March 1, 2005 when the growth had grown and “ruptured” through the skin surface (photos included). At this point, sarcoma salve was employed, completely by the owner. Over a three week period, the salve was applied several times and the owner describes how she diluted the salve to make it more liquid and “injected” (using a syringe without a needle) the diluted salve deeper into the growth as it

peeled away from the normal tissue beneath. The last photo was taken at day twenty from the first application showing only a one to one and one-quarter inch defect healing by second intention. She was euthanized for other reasons (pyometra) several months later, but the growth did not recur.



Izzy - Unidentified Growth Treatment Photo Chronology

Figure 8

Case #3: Cayce McCabe is a female Irish Wolfhound born 1998. On November 11, 2005, she was presented for acute fracture of her right front leg at the distal radius/ulna which subsequently was diagnosed by radiograph appearance in early February 2006 as being an osteosarcoma (no biopsy has been done). The only conventional therapy employed to this point is antibiotic treatment for a period of approximately six weeks in case of osteomyelitis. Treatment has included goldenseal poultices, low level laser therapy, antioxidants, and homeopathic remedies (Symphytum, Hecla lava, Silicea, and Scirrhinum). Neoplasene was added to the poultice beginning in early February and as an oral therapy in late February using a dose of two milligrams per pound b.i.d. She has done very well with the treatment. Her lameness is rarely evident and only if she overuses her leg trying to play. She remains active and energetic with a good appetite, now more than five months from her original fracture, with chest x-rays taken indicating no metastasis. The average survival for those dogs with limb amputation alone is only four-five months and she has surpassed this already.

Case #4: Lucy Schellenberg is a twelve-thirteen year old female Border Collie first presented in February 2005 for mammary tumors, some of which had been present for about four years. The owner elected to start the salve with only one tumor at a time, choosing one that was about two to two and one-half inches in diameter. The tumor was somewhat purple, dark, non-painful, not firmly attached to the underlying tissues and no palpable enlargement of surrounding lymph nodes. I assumed it was likely a benign mammary tumor, but no biopsy was taken. Neoplasene was applied by the owner to cover an area the size of one centimeter on three consecutive days and bandages were applied. He reported that on the third day, she bled from the tumor about 250ml of blood and that it had a central area ~two and one-half inches wide of necrotic black skin surrounded by a one inch wide rim of yellow skin. She lost more blood the next day, but this was the last “bleed”. Over a period of four-six weeks, the tumor continued to shrink and Lucy wanted to lick it “constantly”. A follow-up phone call on June 7, 2005 revealed that the tumor was completely gone. Mr. Schellenberg reported on March 9, 2006 at a recheck visit that the second tumor he treated with Neoplasene was very large (fist-sized) and took a long time to go away, although it did not bleed like the first tumor. What was left was an open granulating wound around which no tumor could be palpated. He was ready to start on the third tumor.

Cases #5 & #6: Pepper Gatzke and Shadow George. These two cases were treated in identical fashion and are included together here. Both are black Labrador Retrievers, Pepper being a thirteen year old female and Shadow being a four and one-half year old male. Pepper was presented in July 2005 with a fleshy growth

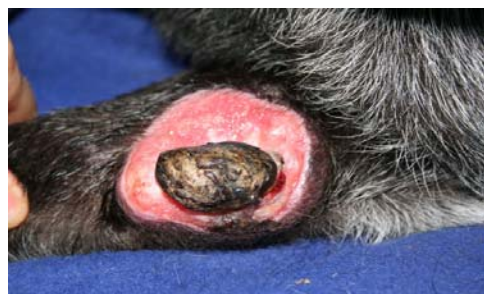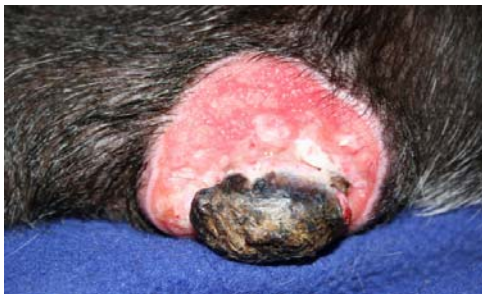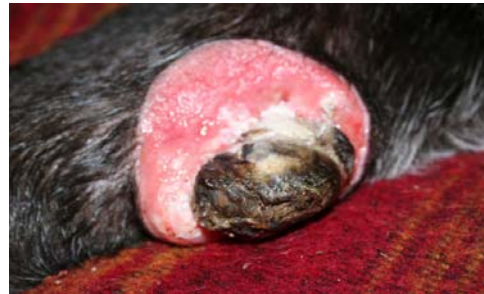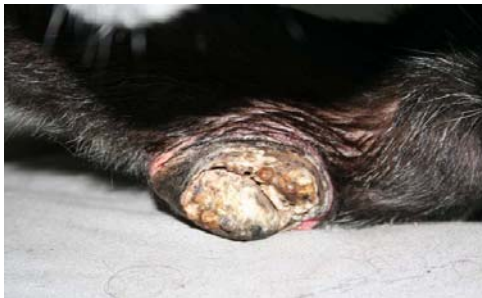with a mottled appearance around the left lower third premolar on both buccal and lingual aspects. The mandible was thickened in the area of the roots of the tooth. Shadow was presented on January 24, 2006 for a second opinion on treatment options for a confirmed maxillary squamous cell carcinoma (well-differentiated) in the region of the upper left canine and first few premolars. CT scan revealed that the growth had not extended into the sinuses.

Treatment consisted in both cases of, under general anesthetic on two different occasions separated by fourteen days, drilling holes into the tumors and “injecting” diluted Neoplasene as well as applying it topically and covering with wet gauzes for a period of one to one and one-half hours. In both dogs, the area affected became very warm to touch and, post-anesthetic, there was some mild swelling associated with the area. In the case of Pepper, the lower premolar three was easily extracted (not due to periodontal disease), indicating involvement of the alveolus, while the other teeth are very firm with no evidence of periodontal disease.

Results for Pepper, whose growth was never histologically identified nor radiographed, are that she is still very much alive and continues to do well. Her owner reports that there is no evident growth remaining and no thickening of the mandible in its previous location. Results for Shadow are also very encouraging. His growth is no longer visible externally on his gingiva and there is no radiological evidence of it. He is due to have a second CT scan in early May 2006.

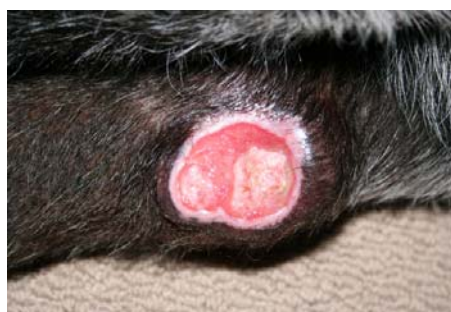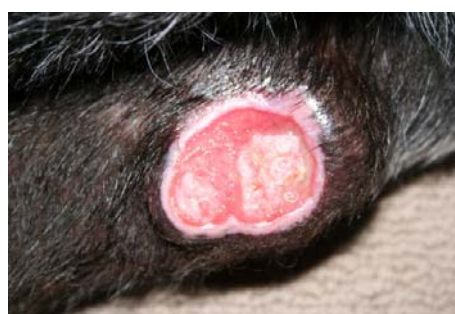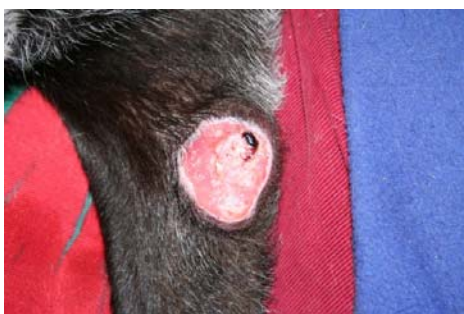Case #7: Blue Hulse is a twelve-thirteen year old male Shepherd cross that was presented on June 27, 2005 with a large two inch diameter protruding mass at the medial aspect of his right elbow. It was not attached to underlying muscle and was non-painful. No treatment was implemented at that time, but he was seen again in early December 2005 and the lump was now about three inches in diameter. Neoplasene was discussed, but not applied until January 5, 2006 when the lump had broken open leaving a defect about two and one-half inches wide. The owner applied the salve several times over the next two months and this is what she writes on March 29:

“Blue’s tumor is doing quite well. It’s not entirely gone - there’s still a bit of a bump at the top - but it’s closing up nicely now. I used the salve three separate times, which is why it’s taken quite a bit longer to heal, but all in all, I’ve been very impressed with the product - the healing balm is also amazing!! In hindsight, for what it’s worth, I think I would have gone straight for the the injection option (inject the salve into the core of the tumor) to speed things up and get to the root, literally. But I’m going to let it heal up and close over now and may give another course of salve in the fall if the bump starts to grow back. In the meantime, I think Blue has had enough with all the bandaging - I’ll give him, and me, a bit of a break.”



Blue Hulse - Unidentified Growth Treatment Photo Chronology

Figure 9



Blue Hulse - Unidentified Growth Treatment Photo Chronology

Figure 10

CASE HISTORY

Terrence S. Fox, Ph.D., P.E.
Buck Mountain Botanicals, Inc.
Miles City, MT

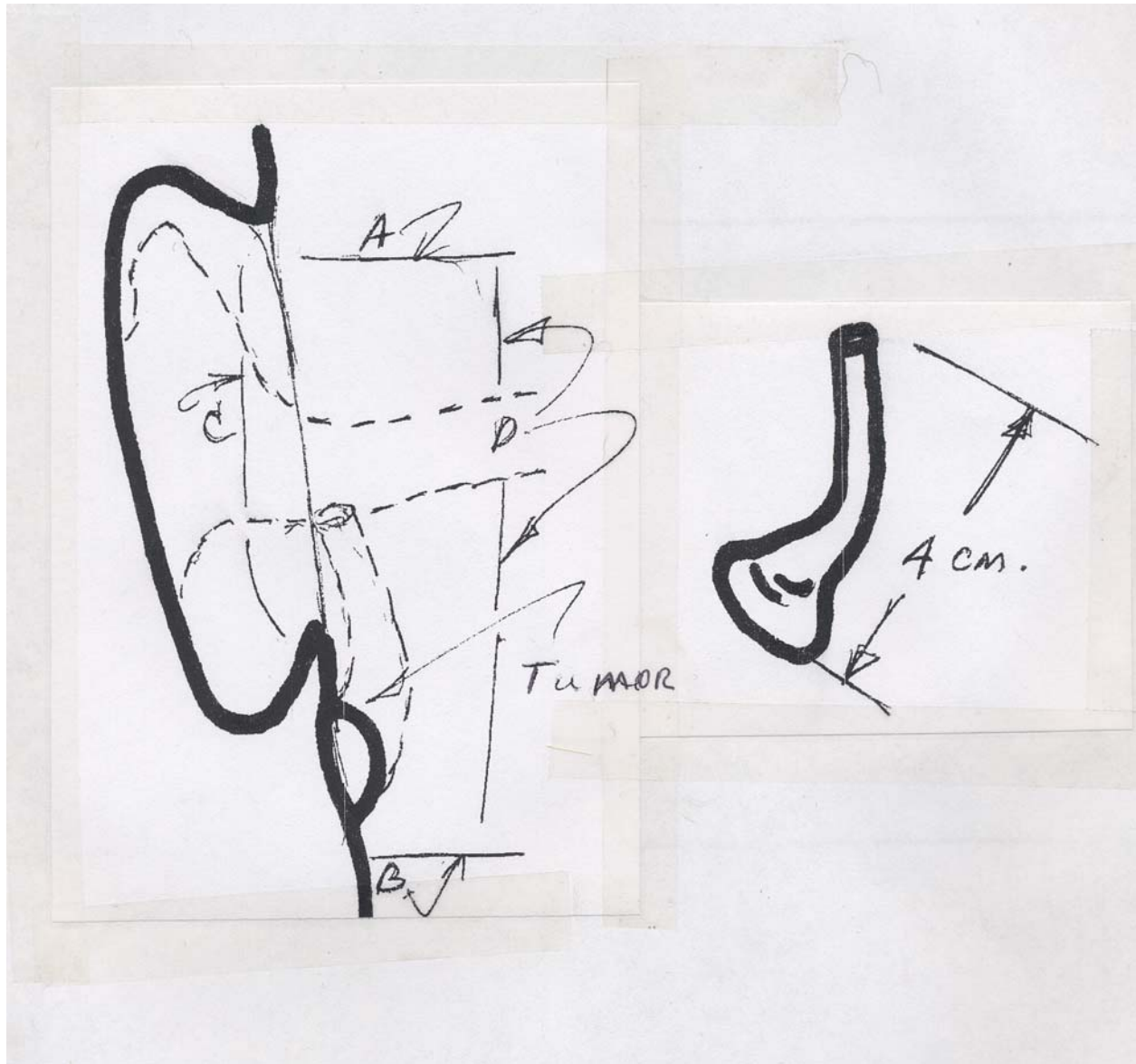
It is noted that I don't recommend that any person should treat themselves or other persons unless they are properly licensed and have obtained appropriate waivers. I treated myself because I have little faith in the allopathic approach of surgery, irradiation and conventional chemotherapy. I have, however, great belief in the drug Neoplasene. In addition, I'm an engineer. We engineers think we can do anything. We can't, but our belief gives us courage to try.

In the fall of 1994 I discovered that the frequency sensitivity of my left ear was compromised. I had thought it was due to lifelong left handed, unprotected use of firearms. The situation began deteriorating in mid-2002 until the hearing was near gone by April 2005. A carcinoma was found just inside the left auricle on the lower external meatus. It was treated three times topically, and three times sloughed off leaving a cavity before it was realized that the major portion of the tumor actually was located behind the lower portion of auricle between the mandible and skull and the tumor had a tentacle that surfaced through the canal, figure 11. With each topical application a portion of the tumor was removed and it was growing back between treatments.

The treatment had caused the immune system to recognize and attack the whole tumor and it became inflamed and sore. Topical Neoplasene was applied to the exposed portion of the tumor behind the lower auricle and a strong reaction ensued. The morning of the sixth day post application a mushroom shaped tumor four centimeters (one and six tenths inches) long separated, figure 11, and instantly hearing was recovered in the ear.

Soreness simultaneously developed over an area behind and on the auricle about seven by three centimeters in size. It was treated multiple times from early September to late November topically and no less than six large tumors were removed (figures 12 & 13). Mast cell indicated.

Beginning December 10, 2005 500 mg. b.i.d. of Neoplasene was administered orally with meals. The immediate effect was the attack of neoplasm located both on the site and remote from the ear which presence was previously unknown. Swelling and soreness of the left lymph node under the chin (i.e. jugular trunk) developed. The entire area which had been treated topically was inflamed and sore and over a



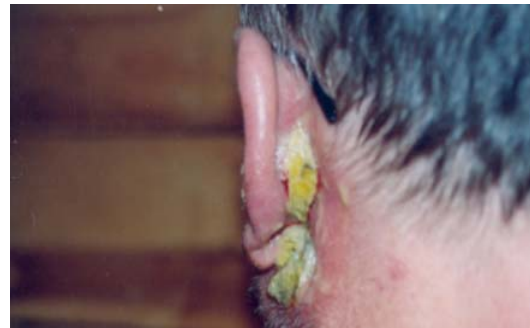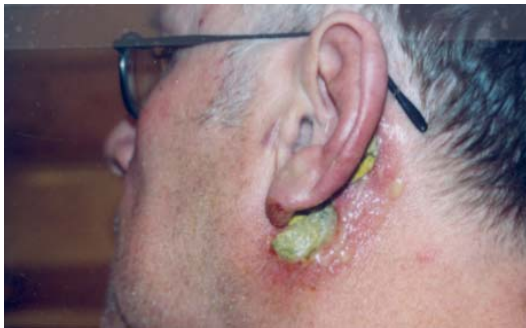T. Fox - Mast Cell Tumor That Impaired Hearing

Figure 11

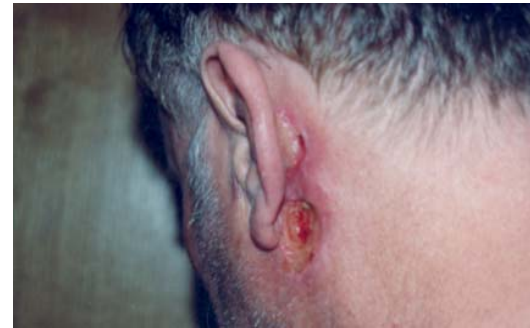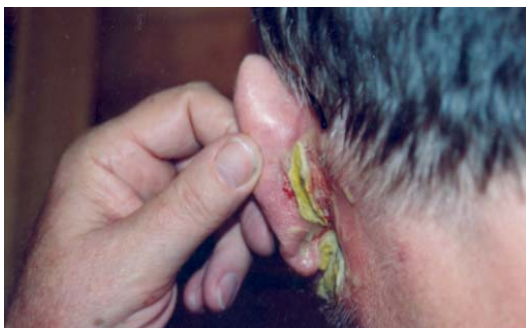three month period became progressively less sore, swollen and prominent. Dosage was increased March 20, 2006 to 750 mg. t.i.d. orally with meals until all soreness disappeared.

In retrospect it is noted that the initial tumor, figure 11, had grown between the numerous bulky tumors behind the ear and posterior to the mandible. It had pinched the canal (i.e. meatus) attenuating then eliminating hearing. Some of the tumors were so large that four topical applications were required to remove them completely. Even so it is noted that oral after care was required to eliminate all neoplasm as it had metastasized to the right ear, right arm, lymph node, forehead and cheek. During the multi-month oral post treatment after care, moles, warts and so called age marks located here and there on arms, legs, head and torso also disappeared.

The side effects were mild gastrointestinal discomfort (i.e. nausea) concurrent to oral treatment.

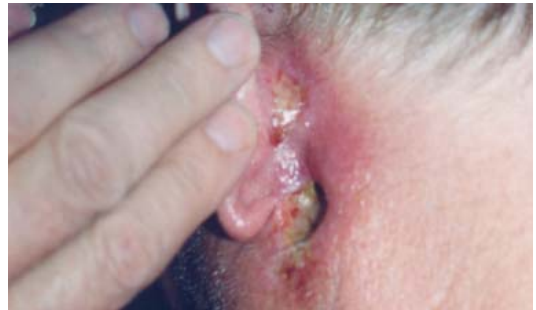
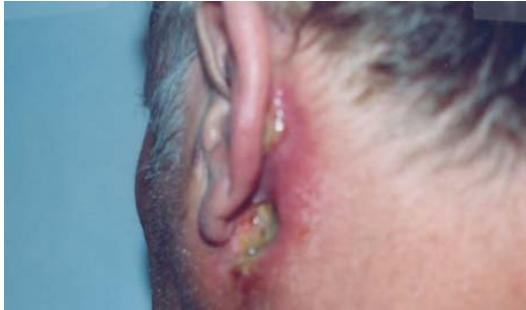
Third topical treatment October 2005

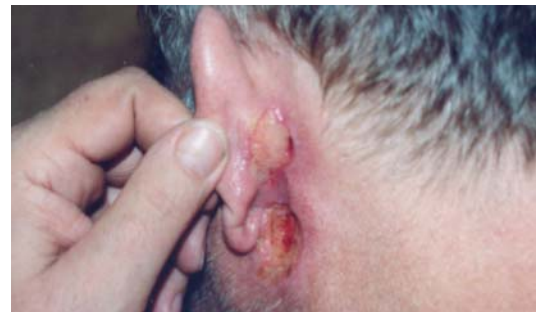
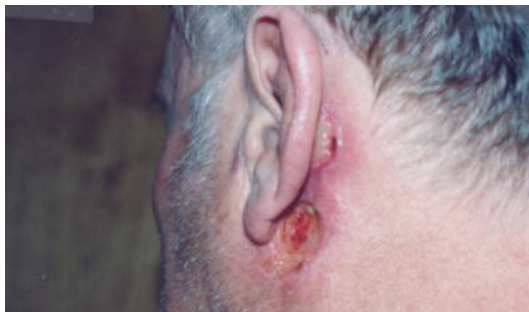
Sloughing of tumor after third treatment

**T. Fox - Mast Cell Tumor Treatment Photo Chronology
Figure 12**



Fourth topical treatment November 2005



Sloughing of tumor early December 2005

T. Fox - Mast Cell Tumor Treatment Photo Chronology

Figure 13

CASE HISTORY

Sarah L. Green, DVM
Veterinary Housecalls
Arcata, CA

Background

Cedar, an eight year old male neutered pit bull terrier mix presented on April 4, 2005 to evaluate a recently noted soft tissue swelling on the dorsal aspect of his right metatarsals. A biopsy performed April 14, 2005 revealed a low grade soft tissue sarcoma of fibroblastic origin. At the time of initial treatment the mass measured three x four centimeters.

The conventional recommendations for soft tissue sarcomas generally include surgical resection with wide margins (at least one centimeter in all directions), followed by irradiation therapy, particularly where adequate margins cannot be obtained. Large tumors on distal limbs frequently pose a problem with regard to closure of the surgical incision even when minimal margins are obtained, due to the lack of sufficient skin at the site. In situations where the tumor is locally invasive and the clients do not wish to pursue radiation therapy, amputation of the affected limb may be offered as an alternative to ensure complete eradication of the tumor. In this case the clients did not wish to pursue an aggressive surgical approach or radiation therapy. Treatment with a bloodroot derived compound ('Sarcoma Salve' from Buck Mountain Botanicals, Inc.) was offered as an alternative.

Treatment

The dog was treated a total of three times over a nine day period as described below. (The letters in parentheses refer to the corresponding digital photographic images.) The tumor mass sloughed in its entirety four days after the third treatment. The remaining wound healed uneventfully by second intention over a period of six weeks. During this time the only wound care required was once daily irrigation with hydrogen peroxide and the application of a fresh bandage. As of this writing, eleven months after the initial treatment, there is no gross evidence of tumor recurrence.

Treatment 1: The tumor and surrounding skin were clipped and cleaned with a Chlorhexadine surgical scrub. The tumor was punctured at multiple sites with

an eighteen gauge needle to enhance penetration of the Sarcoma Salve. A layer of salve approximately five tenths centimeter thick was applied to the entire surface of the tumor. The treatment site was then covered with gauze sponges and bandaged for a period of ten hours. After this time the bandages were removed and the treatment area rinsed with hydrogen peroxide. At this point several areas of tissue necrosis were already evident at the center of the tumor mass, primarily surrounding the previous biopsy sites. Following treatment the site was coated with a topical dressing containing Yarrow, Burdock and Echinacea ('Wound Balm' produced by Buck Mountain Botanicals) and bandaged.

Treatment 2: Cedar was rechecked the following morning and an additional treatment performed as described above. By that evening a larger area of discoloration and presumed tissue necrosis was evident. The paw was mildly swollen and the client reported that Cedar had appeared uncomfortable throughout the day. A single injection of the non-steroidal anti-inflammatory drug Meloxicam was administered subcutaneously. Cedar was next rechecked three days later. At this time the dorsal and superficial layers of the tumor had begun to separate from the surrounding tissue and large areas of necrosis were evident within the tumor mass. No further discomfort was reported at this visit.

Treatment 3: Cedar was next rechecked four days later. The skin overlying the tumor mass had completely separated from the surrounding skin and an extensive area of necrosis was present at the center of the tumor. The tumor tissue at the periphery of the mass however, still appeared viable, so an additional application of salve was performed. On this occasion Cedar appeared uncomfortable and agitated immediately following application of the salve. He was treated again with a single injection of Meloxicam as well an opiate analgesic/ sedative combination of Butorphanol and Acepromazine. The Sarcoma Salve was rinsed and Wound Balm applied post treatment as previously. Three days after this treatment the entire tumor mass appeared necrotic and had partially separated from the underlying tissue. The client reported in a telephone conversation the following day that the mass had sloughed, leaving no visible residue of diseased tissue. She continued to cleanse the area daily with hydrogen peroxide, apply Wound Balm or a triple antibiotic ointment topically and bandage the area as directed.

When the wound was rechecked four days later the remaining tissue appeared healthy. There was no evidence of pain or inflammation in the surrounding area. On subsequent visits normal wound contracture was observed. At a six month

follow up there was no gross evidence of tumor recurrence and hair re-growth had occurred over approximately three fourths of the original treatment area.

Comments

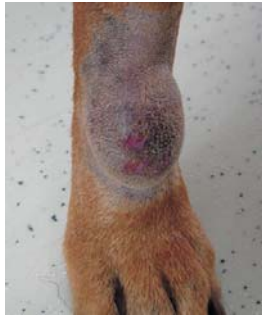Although a follow up biopsy was not performed the tumor described above appears to have been successfully removed without the use of surgery or irradiation. Since treatment of this patient, the author has subsequently used 'Sarcoma Salve' (now 'Neoplasene') in the treatment of other soft tissue sarcomas and carcinomas, including a hemangiopericytoma, peripheral nerve sheath tumors, squamous cell carcinomas, an oral melanoma, and an apocrine cell carcinoma, as either the sole method of therapy or following surgical debulking of the tumor mass. Although limited, these experiences and those of other practitioners suggest that the bloodroot compound used here effectively differentiates between neoplastic and non neoplastic tissue, causing rapid and profound necrosis of the neoplasm without harming the adjacent healthy tissue. The use of this compound is an effective alternative to surgery and radiation in the removal of small to medium size cutaneous and subcutaneous neoplasms and a useful adjunct to surgery in the removal of larger masses. The potential benefits of a therapeutic agent that differentiates neoplastic from non neoplastic tissue at the cellular level are enormous. These would include not only the successful eradication of neoplastic cells beyond the visible margins of a mass, but also elimination of the need to remove large amounts of healthy tissue to ensure 'clean margins'. Furthermore, in situations where this treatment is used as the sole therapeutic modality, anesthesia is generally not needed, with the possible exception of intraoral neoplasms, or those in very close proximity the eye.

The primary drawback to this treatment modality is the need to manage an open wound. Counseling clients ahead of time regarding the expected progression of treatment is undoubtedly important. This author has found the use of the images included here to be very helpful in presenting this modality to subsequent clients. The use of adjunctive therapies such as medical ozone may also decrease healing time and minimize the risk of infection.

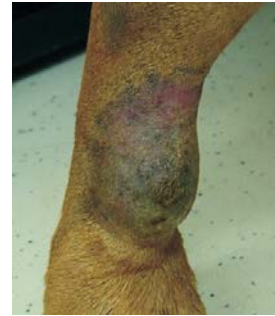One issue which warrants further consideration is the subject of pain and discomfort experienced by the animals during treatment. In this author's limited experience there is a great deal of variability dependant on the type of tumor and its location. To the extent that it is possible to subjectively qualify and compare

levels of pain in other species, it would appear based on veterinary staff and client observations, that pain levels range from minimal in the case of squamous cell carcinomas on the face and ears of cats to moderate to severe in the case of distal limb sarcomas such as peripheral nerve sheath tumors. The more intense pain appears to occur during a twenty-four to forty-eight hour period following treatment, during an acute inflammatory phase of response to the therapy. Whether this is due to local tissue reaction or to swelling of the limb distal to the site has been difficult to determine. Although it has been suggested that the inflammation associated with the treatment is integral to the patient's immune response and therefore should not be suppressed, it is the author's opinion that we are obligated to minimize pain whenever possible.

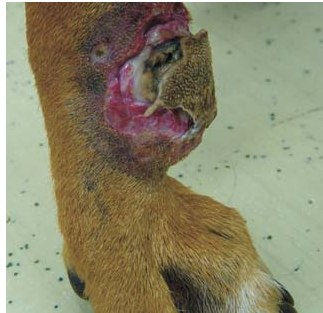As increasing numbers of veterinarians begin to incorporate this form of treatment into our collective medicine bags, we will hopefully be able to pool our combined experiences to further refine and expand upon the treatment protocols that Terry Fox and others have generously shared with their colleagues.



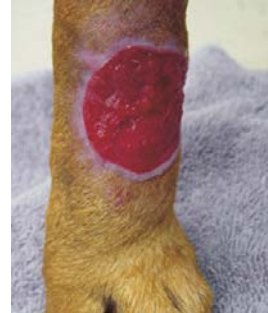4/28/05 pre-treatment



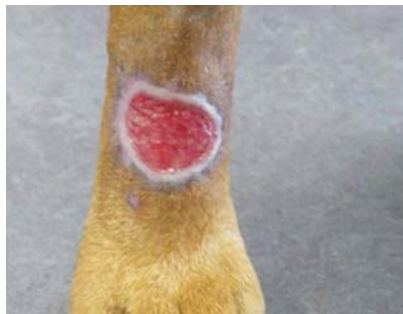4/29/05 post treatment



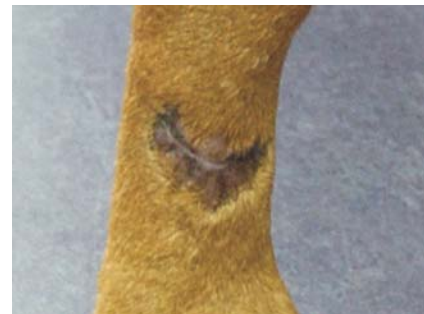5/2/05 separation



5/23/05 granulation



6/3/05 healing



11/8/05 end result

Cedar - Soft Tissue Sarcoma Treatment Photo Chronology

Figure 14

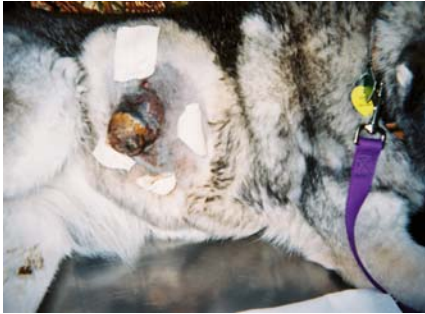
CASE HISTORIES

Cheryl L. Haass, DVM
Woodland Animal Health Center
Seymour, WI

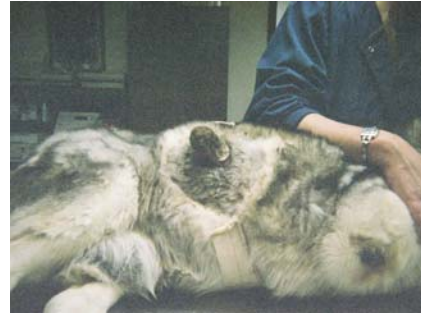Case #1: Kodi Dercks is a neutered male Husky mix. Kodi was diagnosed (via excisional biopsies) with grade one malignant liposarcoma on February 15, 2005. This tumor was cylindrical, about one and three tenths inches diameter, and stuck straight out from his ribcage about three inches, thus rubbing or catching on things as he walked around the house. Due to advanced age and multiple other health problems (including but not limited to heart block, laryngeal paralysis, and osteoarthritis), we referred the dog to a university teaching hospital, where it was determined that the tumor had invaded into and beyond the adjacent rib and was probably in the pleural cavity already. He was rejected for both surgery and radiation therapies and was sent home (owners declined to have a pacemaker implanted).

Several options were proposed and rejected, but Kodi's owners were very interested in the use of a topical botanical product to manage his cancer and we discussed using Sanguinaria (Buck Mountain Neoplasene a/k/a Sarcoma Salve #1) at great length. We began treatment on April 15, 2005 by applying a small amount of salve to the top of the mass, and covering with a moist bandage. Being on the ribcage, we had to bandage right around the dog every time. Poor Kodi! He really hated those bandage changes, but we did them every three to four days, with cleaning and re-application of salve at each change. Perhaps because of the relatively "quiet" nature of liposarcoma, it took time for evidence of a response to be seen. I began applying the salve more liberally. Eventually, the surface began to ulcerate and in time, a "break" appeared at the base of the mass, which slowly encircled it, and the mass seemed to shrink like a deflated balloon. We continued using the salve and allowed it to work down into the tissue bed until we felt that all the cancerous tissue had been ferreted out – there were several foci ventral to the original mass that were not visible as tumors, but reacted strongly to the salve. The entire process took about five weeks. The resulting open wound healed well and fairly quickly, granulating in and leaving only a relatively small area of scar tissue – about the size of a dime.

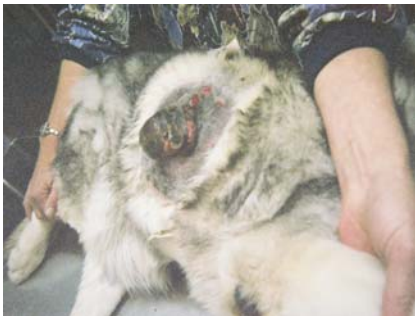4/16/05



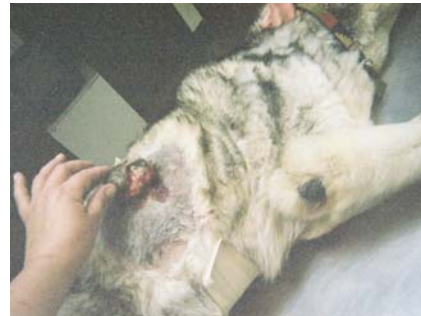4/29/05



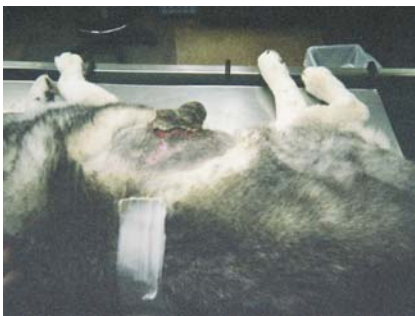5/3/05



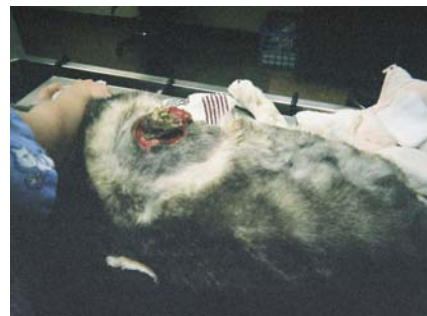5/10/05



5/14/05



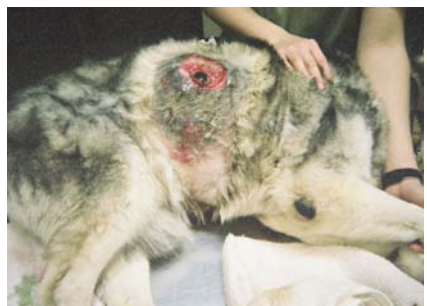5/20/05



5/24/05



5/24/05



Kodi - Liposarcoma Treatment Photo Chronology

Figure 15

This was a good treatment choice for a dog which had been “written off” by conventional medicine, and where multiple significant health issues were present. There were no significant adverse effects observed, other than some discomfort or burning at the tumor site when the salve was applied.

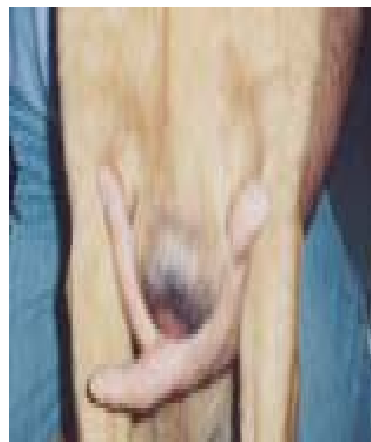
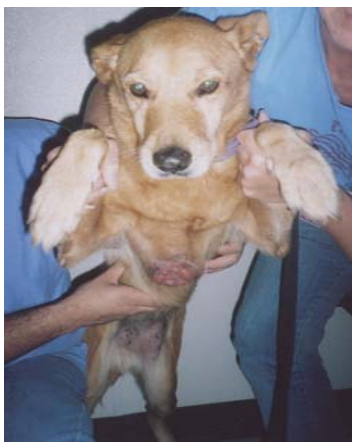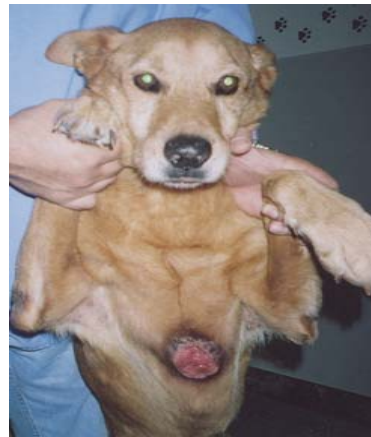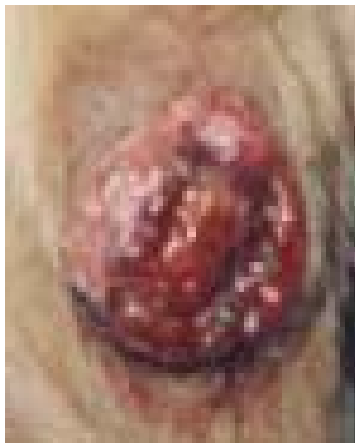Case #2: Missy D. is a spayed female Labrador Retriever. Missy had surgery on July 12, 2005 to excise a firm, rapidly growing and bleeding connective tissue mass from her left elbow. The mass was deeply attached and complete excision was unlikely. Unfortunately, the owner declined histopathologic exam of the tumor, but the presumptive diagnosis was a connective tissue sarcoma. Within sixteen weeks, the mass returned and was as big as ever. Further surgery was declined, and other options such as radiation were declined. After discussion with the owner, treatment with Neoplasene was accepted. We began the treatment on October 28, 2005 applying the salve and bandaging the elbow, and after a few bandage changes the owner took over and treated the lesion at home, although we continued to check it weekly. The lesion began to necrose within a week and was completely gone by December 16, 2005. The dog seemed to experience some burning or tingling when the salve was first applied, but other than minor problems with edema and bandage rubbing at the area of the elbow, there were no adverse effects observed. So far she is doing well after two months.

This treatment proved to be an excellent option for the owner, as opposed to aggressive surgery, amputation, or radiation therapy; the cost was limited, there was no debilitation associated with the process, and the result was excellent. We will continue to monitor this case as long as possible.

CASE HISTORY

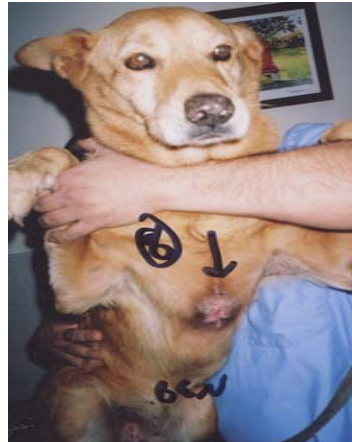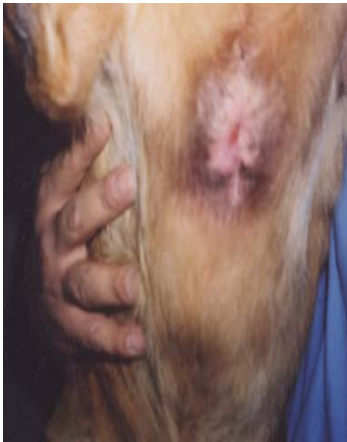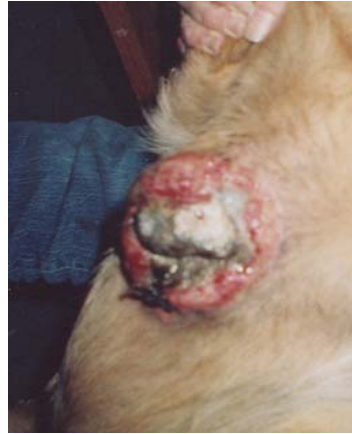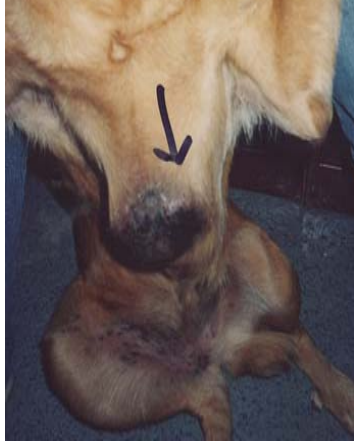Timothy W. Harkness, DVM, BS
Chief Veterinarian Houston Humane Society
Houston, TX

Case #1: Ben, a twelve year old Labrador Retriever mixed breed was presented with a rapidly growing mass on his chest which had been open and draining for the past two months (mixed cell tumor). We applied Neoplasene topically every twelve hours and kept it under a tight wrap. Ben received seven days of treatment. Eighteen days from an open mass to almost completely healed.



Ben - Mixed Cell Tumor Treatment Photo Chronology

Figure 16

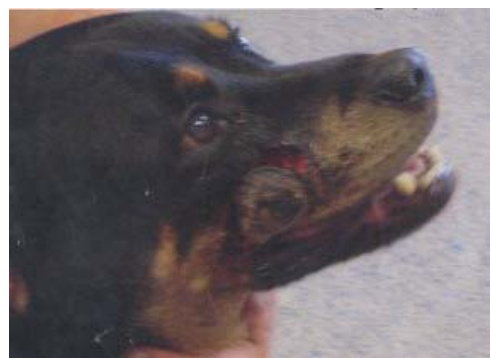
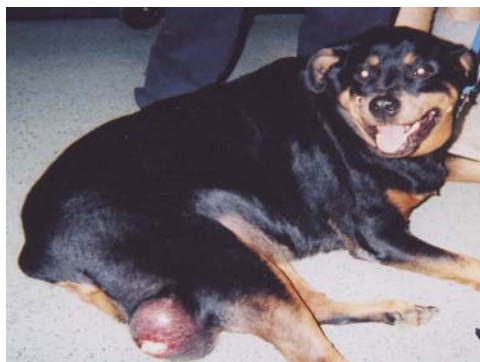
Ben - Mixed Cell Tumor Treatment Photo Chronology

Figure 17

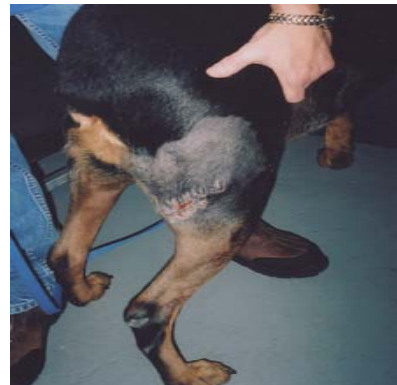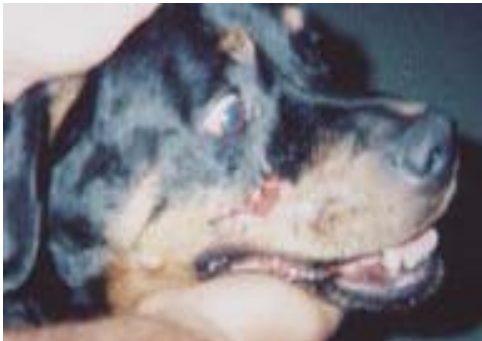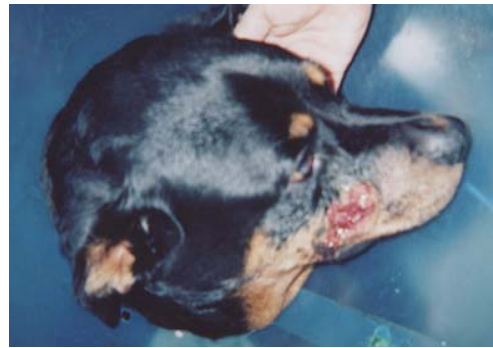
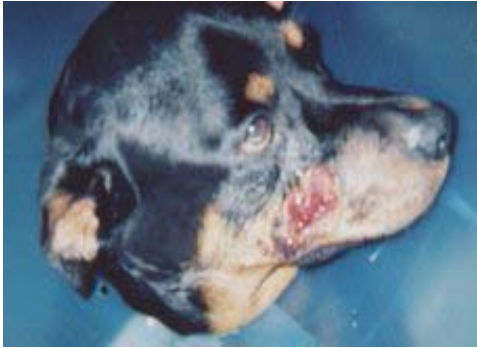Case #2: Rosie, a twelve year old female Rottweiler, spayed, fairly good physical condition but not a candidate for surgery due to age. Primary complaint was that a fast growing mass on the side of the face, about three months in duration, with concurrent large mass on the right rear limb – two year duration. This was a difficult area to treat on the side of the face. The dog would lick off the salve about as fast as it was put on. A teaspoon of salve was mixed with twenty cubic centimeters of sterile saline solution filtered through sterile gauze (a/k/a NeoplaseneX with saline) and injected into the mass at the side of the face with a total of two cubic centimeters injected into the facial lesion. After the third day post treatment there was a vast amount of swelling in the facial region. The owner became concerned and the animal was placed on some lasix, ectogesic, and cephelexin. The swelling went down by the sixth day post treatment. A line of demarcation was noted around the facial lesion on day five post injection. The mass fell off day eight post injection.

Interestingly, during the treatment process the mass on the rear limb shrunk by fifty percent indicating systemic involvement of the drug to other areas of neoplastic involvement. At this point, the mass on the back limb was removed with the use of a local nerve block due to its size. Laboratory results showed that it was a spindle cell sarcoma. Total recovery was achieved by December 20, 2005. The subject has gained ten pounds since the initial treatment.



Rosie - Unidentified Growth Treatment Photo Chronology

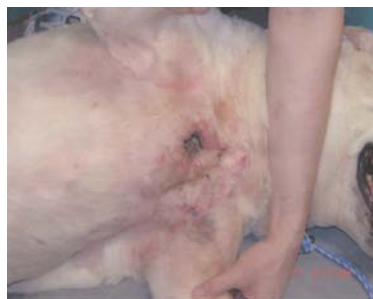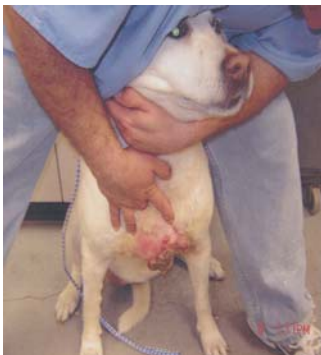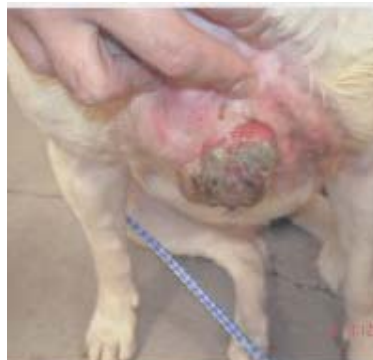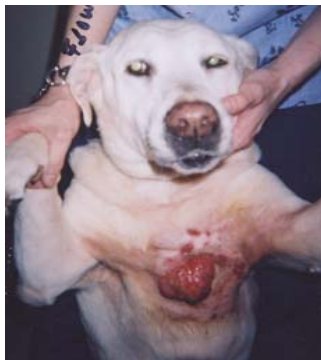Figure 18



Rosie - Unidentified Growth Treatment Photo Chronology

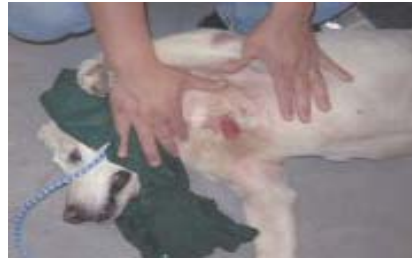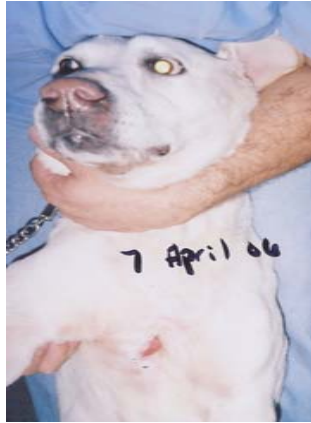Figure 19

Case #3: Flower, a fourteen year old female Yellow Labrador Retriever, spayed, was presented with a very aggressive chest mass. Their previous veterinarian sent them to a referral center which had a treatment cost that would have exceeded \$3,000. Neoplasene therapy was their last resort. Treatment was started with Neoplasene around November 2005 by applying it b.i.d. for three days (kept under a wrap). The mass started to die but it had many fingers spread around the central mass. The mass was injected with six cubic centimeters of NeoplaseneX and the patient was started on two hundred fifty milligrams oral s.i.d. for fourteen days. I again injected the mass with six cubic centimeters of the solution and applied it topically s.i.d. every twenty-four hours tightly wrapped for a total of five treatments. The mass is in total remission as of this date. The treatment course was modified slightly and produced good results. The animal has gained ten pounds in body weight. This mass was an acute malignant fibrosarcoma. The total charge to the client was \$125. The treatment took longer but was well worth the time and the effort for the patient and the client.



Flower - Acute Malignant Fibrosarcoma Treatment Photo Chronology

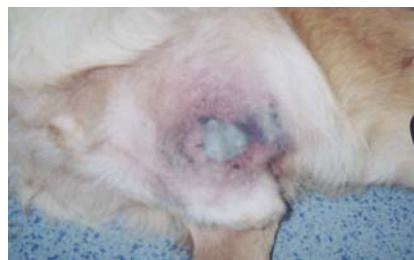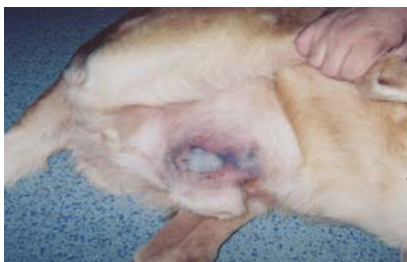Figure 20



Flower - Acute Malignant Fibrosarcoma Treatment Photo Chronology

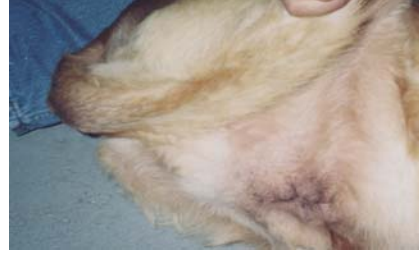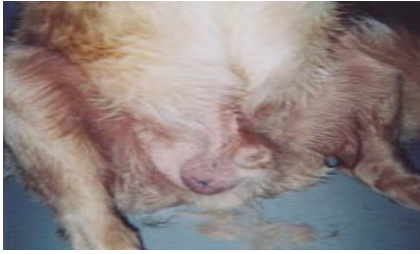Figure 21

Case #4: Alex, a thirteen year old neutered male was presented with an open mass of six months duration beside his penis yielding dysuria and pelvic pain. He had loss of appetite and loss of muscle mass. Initial treatment was five cubic centimeters injection with NeoplaseneX along with topical treatment b.i.d. for three days. The first photo was taken day five post injection. The second photo is day seven post injection. The third photo is day fourteen post injection and the last photo is day twenty-one completely healed. The mass was a papilliferous cyst-adenocarcinoma.



Alex - Papilliferous Cyst-Adenocarcinoma Treatment Photo Chronology

Figure 22

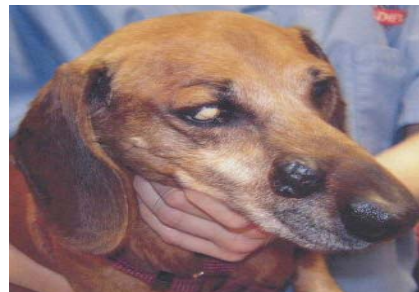
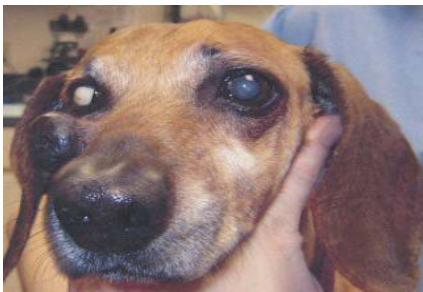
Alex - Papilliferous Cyst-Adenocarcinoma Treatment Photo Chronology

Figure 23

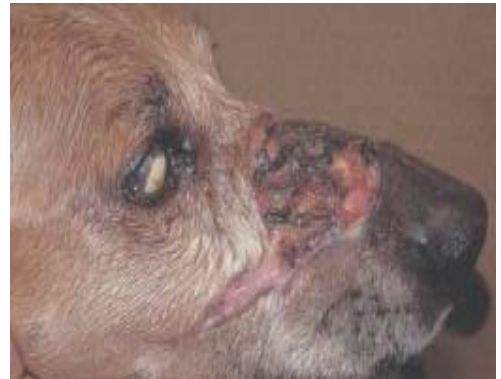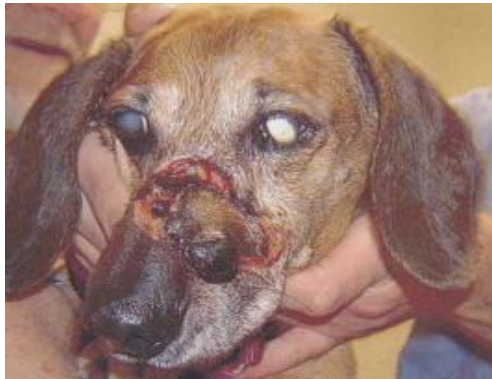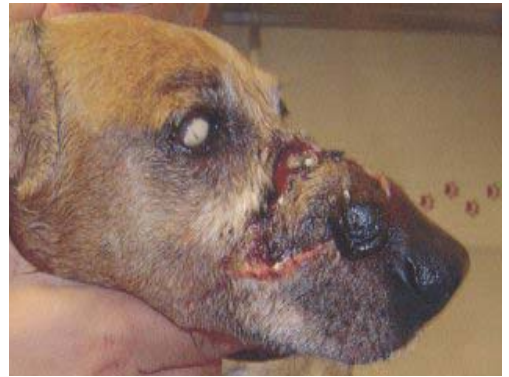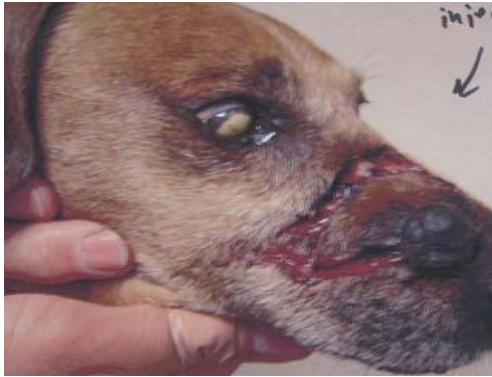Case #5: Cowboy, a fifteen year old neutered male Dachshund mixed breed was presented with a black in color lesion on the side of his face. The lesion had been present for about four years and has doubled in size the past month. The owner was concerned. The subject is blind in one eye but otherwise in fair physical condition. The owner had been to two previous veterinarians for treatment and was declined due to the dog's age and the risk factor of surgery. Treatment was started on March 6, 2006. The lesion was injected with six tenths cubic centimeter of NeoplaseneX directly into the center of the lesion. The subject became anorexic for thirty-six hours post injection. The subject was placed on Canine Rebound Electrolyte (oral) during this period.

The subject's temperature held at about 103.2 then returned to normal about day five post injection. The laboratory results showed this mass to be a malignant melanoma. Radiographs of the chest are still clear as of this date. The mass had fingers extending deep within the facial tissue according to the photographs. Routine surgery would not have removed this mass in its entirety.



Cowboy - Malignant Melanoma Treatment Photo Chronology

Figure 24



Cowboy - Malignant Melanoma Treatment Photo Chronology

Figure 25

CASE HISTORIES

Betsy A. Hershey, DVM, DACVIM (Oncology)
Integrative Veterinary Oncology, PC
Phoenix, AZ

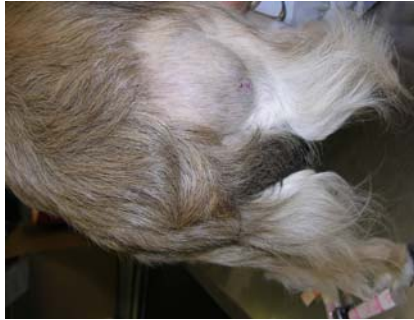Our clinic has recently started using Neoplasene products as treatment for unresectable tumors. The topical paste appears to have the most efficacy in causing apoptosis, necrosis and sloughing of tumors. The oral administration of Neoplasene appears to be best as an adjunct to the topical, Neoplasene, or IV, NeoplaseneX, and does not appear to have as much effect when used as a sole, primary treatment.

We have recently started using IV NeoplaseneX for internal masses. Although the recommended administration is to start at one and one-half milligrams/kilograms twice daily and increase as indicated, this schedule is impractical for most clients and we have been investigating a modified schedule of administration. At present we have been giving up to twenty-five milligrams/kilograms (i.e. eleven milligrams/pound) of IV NeoplaseneX administered once to twice weekly. At this dose, significant tumor necrosis/apoptosis occurs; however GI side effects are significant with vomiting, lethargy and inappetance that can last up to three days post treatment in some patients. Additionally, in three of three patients treated with an IV bolus of NeoplaseneX at a three:one saline/NeoplaseneX ratio given over five minutes, we have seen anaphylactic reactions with collapse and hypersalivation. Immediate cessation of the IV bolus followed by IM benadryl reversed the reaction in all patients. Diluting the NeoplaseneX in 150 ml of saline and infusing over two hours has appeared to ameliorate this side effect. Gastrointestinal distress can be minimized by pretreating with anti-emetics such as metoclopramide, dolasetron or ondansetron thirty minutes prior to starting the infusion. Two of the three patients were ultimately changed to topical administration with improved results. One patient with a urethral transitional cell carcinoma has responded well to the combination of oral and IV administration in combination with piroxicam and Chinese herbals, with significant improvement in her ability to urinate since starting the IV treatment.

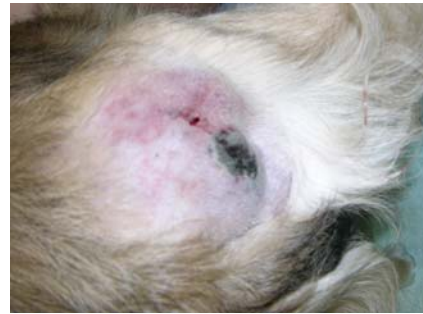We have primarily treated soft tissue sarcomas with topical Neoplasene, but are also treating several patients with mast cell tumors, carcinomas, and cutaneous lymphomas. Many of our patients present with tumors that have recurred after previous surgery and/or chemotherapy. Most tumors are five centimeters or

greater in diameter and considered to be nonsurgical. In subcutaneous tumors where the overlying skin is intact, the salve has first been injected into the tumor to start the reaction. We accomplish this by mixing five tenths milliliter of the Neoplasene paste with twenty milliliters of DMSO. The use of DMSO has reduced the significant inflammatory and pain reaction that accompanies the initial injection into the tumor. Approximately four to five days post injection the overlying skin begins to necrose and the patient is sedated for debridement of the necrotic skin. In many patients the underlying tumor has already begun to react and can be debrided in part or in full at which time the salve is applied topically. For extremely large tumors, the process of complete sloughing of the tumor can be as long as two months with daily to every other day topical application and the healing process as long as two to three months. During the treatment phase, occasional "breaks" of four to five days are given to allow the necrotic tissue to slough in order to evaluate the remaining diseased tissue for additional treatment. Once the tumor bed is open, a bandage is applied and changed daily. The tumor bed is irrigated with saline before reapplication of salve. Because application causes significant pain when administered to the open tumor bed, we have begun irrigating the tumor bed with one part bupivacaine to three parts DMSO prior to reapplication of Neoplasene. The wound is then covered in Wound Balm before rebandaging. With the exception of mast cell tumor patients, which receive prednisone, patients are administered daily piroxicam. All patients receive tramadol for pain. Patients also receive prophylactic antibiotics with cephalixin. Ciprofloxacin is administered to patients that develop pseudomonas infections. Despite the lengthy treatment period in most patients, we have not observed severe or resistant infections in any patient. Once the tumor has been removed, the patients are administered oral Neoplasene for three months. Results have been tremendous and none of the treated tumors have recurred in the nine months we have been using the Neoplasene. The following cases are examples of our success with topical Neoplasene.

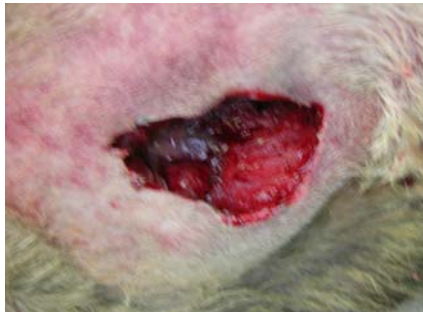Case #1: Roxie, a seven year old spayed female Chihuahua mix was diagnosed with a peripheral nerve sheath tumor overlying her right ischium. The tumor measured six centimeters in diameter. Although this was the initial occurrence of the tumor, the owner declined standard of care therapy with surgery and radiation therapy. An initial injection was administered and five days later, Roxie was sedated for debridement. The majority of the tumor was necrotic and able to be debrided. One additional topical treatment was administered. The reactive process lasted approximately one month with an additional month for the wound to heal. She is currently doing well with no recurrence of the tumor three months post treatment.



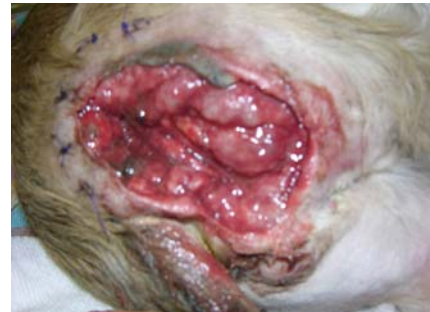Pretreatment



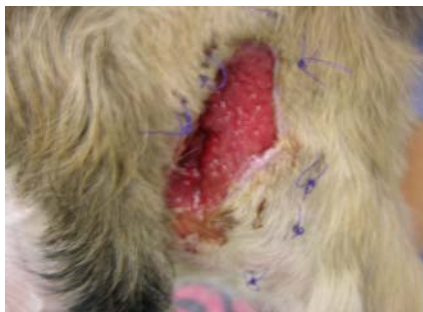Four days post initial injection



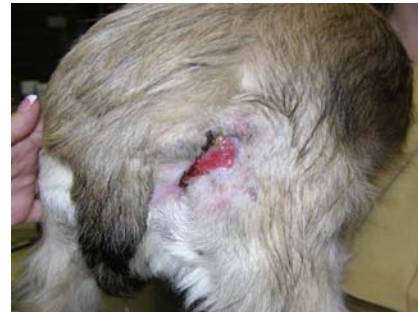After initial debridement of tumor on day 4



Three weeks into treatment



Six weeks post treatment



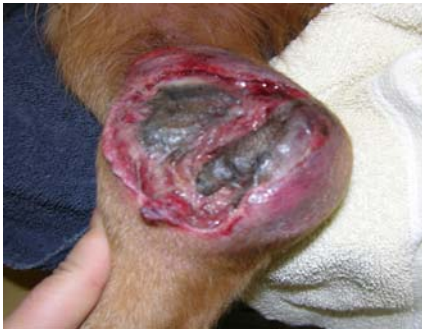Eight weeks post treatment

Roxie - Nerve Sheath Tumor Treatment Photo Chronology

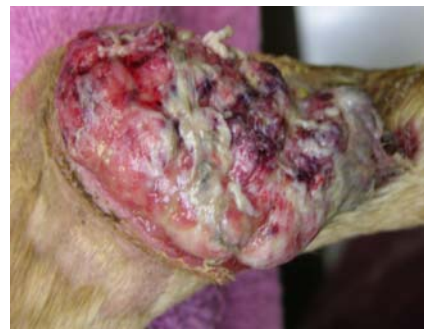Figure 26

Case #2:

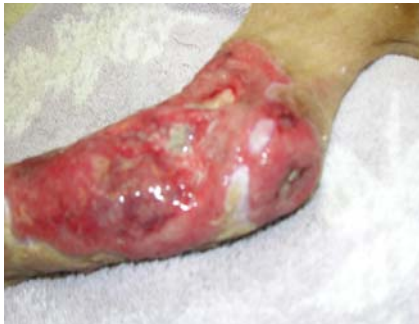Jasmine, a ten year old spayed femal Labrador Retriever was diagnosed with a large nerve sheath tumor involving the left lateral hock. The tumor measured nine cm in diameter. Conventional treatment would have required an amputation of the leg. Her treatment has been lengthy with nearly two months required for complete slough of the tumor. She had an almost circumferential wound with exposure of multiple tendons once the tumor had sloughed. It has taken nearly three months for the wound to granulate.



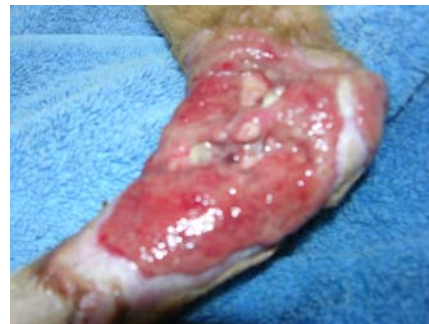Four days post initial injection



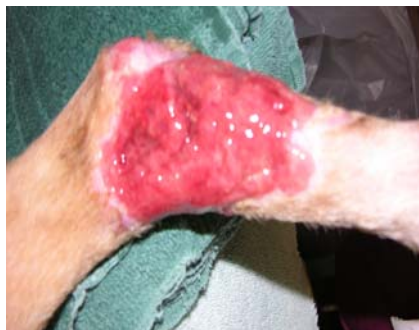Two weeks into treatment



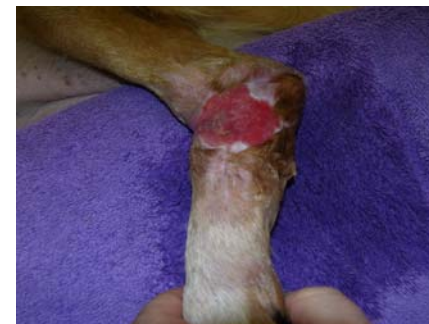Eight weeks end of treatment



Ten weeks post treatment



Fifteen weeks post treatment



Twenty weeks post treatment

Jasmine - Nerve Sheath Tumor Treatment Photo Chronology
Figure 27

CASE HISTORIES

Mark C. Ingram, DVM
Franklin Road Animal Hospital
Brentwood, TN

Case #1: My first experience with Neoplasene was with my own horse, a quarter horse named Toms Choctaw Boy, in August of 2001. “Tom Boy” had developed an ugly cancerous lesion on his right ear; he was only two years old and just being trained. You wondered every time you put a bridle over that ear. I had read about Neoplasene and had some at the clinic for just such a case. I mixed the Neoplasene with petroleum jelly and applied it to his ear. It was never wiped off. I only went to the farm where he was three times a week. About a week later the lesion looked rough. A few days later I surgically removed the lesion with narrow margins because of the lack of movable tissue on the ear. Histopathology confirmed it to be a sarcoid. With all rights it should have returned, especially considering the close margins. Five years later it never has.

Based on this limited anecdotal experience, compared to years of experience with equine sarcoid, I would recommend treating lesions prior to surgery to prevent the almost sure recurrence of the lesions.

Case #2: There have been other cases before Elvis, but he exemplifies owners’ desperation and love for their charges. Elvis came to me in May 2004 as a cancer consultation, a nineteen year old cat with sarcoma in the region of the left hock. Hair analysis, laboratory work, subsequent vitamin-mineral recommendations, corticosteroids (Pletcher) held the sarcoma at bay for one and one-half years. Then, as it enlarged, ultrasound therapy was employed at obviously not high enough rates to control or kill it. Neoplasene therapies were suggested early on, but initially rejected due to adverse input. It was so large and rapidly growing that it was affecting his life. She decided that she had rather take a chance at a cure than to just put him to sleep. The owner did internet investigations and came to the conclusion it was the only hope for Elvis.

The tumor was injected with Buck Mountain Sarcoma Salve dissolved in DMSO (a/k/a NeoplaseneX with methyl sulfoxide) over a period of weeks, during which the massive lesion necrosed. Contrary to recommendations, the necrotic tissue was removed so as to not burden the body.

On February 10, 2005 the tumor was five by six centimeters and one and two tenths cubic centimeters of NeoplaseneX with DMSO was injected medial to the hock. He was next seen on February 23, 2005 and the tumor was about six and one-half by four and one-half centimeters. Three tenths cubic centimeter of NeoplaseneX with DMSO was injected. Necrosis was evident from the previous injection. Penicillin injections were added because of his refusal to take oral medications. He maintained use of the leg. On March 2, 2005 Ringers is administered, SQ. penicillin injections continued, one cubic centimeter of NeoplaseneX with DMSO injected and necrotic tissue gently debrided to reduce the body's toxic load. On March 8, 2005 Elvis was seen again, more fluids, corticosteroids, applied kinesiology for homotoxicology, vitamin, mineral supplements and antibiotics, debridement, and more NeoplaseneX with DMSO injections (one and one quarter cubic centimeters). Over half the tumor was gone. On March 16, 2005 he was dropped off at the clinic, not doing well, in kidney failure. The wound was cleaned out with hydrogen peroxide. Over ninety-five percent of the tumor was gone and he was still using his leg.

The operation was a success, but the patient died a few days later. In hind site, Elvis's attitude and Denise's inability to administer medication was a factor. Money and the mental stability of a twenty-one year old cat made hospitalization impractical. Denise hated the tumor that had attacked her longtime friend and was excited to see it rot. She stated that she wished she had pursued the Neoplasene option years ago when first mentioned and Elvis had more vitality. The tumor, though held at bay for a while, had become much more aggressive as Elvis's body deteriorated with age. The tumor was over ninety-five percent gone when Elvis succumbed to kidney failure. Denise, the owner, although sad at his passing, was angry that we were so close to defeating the tumor, and regretful that it had not been started sooner.

Case #3: Tahoe had been diagnosed as having a tumor on his right lateral toe in August 2005. It was removed and supposedly confirmed as a mast cell tumor by cytology at another clinic. In January 2006 the right front medial toe was examined. It was concluded to be another mast cell occurrence or a nail bed injury with pain and inflammation to the metacarpal joint. A skin scraping was made, mast cells noted, and a lab diagnosis of mast cell carcinoma made somewhat based on history. The medial toe was removed and Neoplasene (a/k/a Sarcoma Salve #1) applied to the remaining reddened tissue of the second phalanx. The bandage was not removed by the owner for about twenty-two hours.

Eventually all the initially reddened area at surgery sloughed off. Histopathology of the submitted toe did not support mast cell tumor, as was initially indicated, but a severe demodicosis. It was appropriately treated in this and two other feet and he eventually recovered, although missing two toes. The owner is a bit upset with the first veterinarian who did not submit the toe to the lab and wonders if the whole thing could have been demodicosis. The tissue was abnormal and inflamed, but not neoplastic, the best we can determine.

Lessons to learn are the twelve hour not twenty-two hour application, and mast cells occur in inflation. We do not know if it might not have sloughed if only on for twelve hours. The defect has now scarred in and Tahoe is using all four legs.

Case #4: Sam is a nine year old, one hundred six pound hound mixed breed that was diagnosed with mast cell cancer, which was subsequently removed along with much surrounding tissue. Sam's friends decided not to continue with the chemotherapy since it caused him so much distress. On our first visit December 15, 2005 we did detox on Sam, hair analysis, nutritional changes, and much antioxidant supplementation. Sam was put on a Chinese herbal combination recommended by Steve Marsden with some modifications. Interestingly, hair analysis did not show a pattern of illness, but low cobalt, high iodine and high bismuth.

On April 14, 2006 Sam returned to the clinic; he had been off the Chinese herbal combination for about two weeks and had an inch diameter pruritic lesion next to the previous incision site. The lesion was injected with one and one-half cubic centimeters of NeoplaseneX with DMSO. Much swelling occurred ventral to the lesion and the mass fell off. Sam was also put on oral Neoplasene, one hundred eighty milligrams twice a day. On April 27, 2006 he was seen again with two smaller lesions near the area of the previous ventral swelling. These were injected with one and one quarter cubic centimeters of solution. This is a work in progress and more investigation as to why continues.

CASE HISTORIES

Alan B. Lippart, DVM
Markesan Veterinary Clinic, SC
Markesan, WI

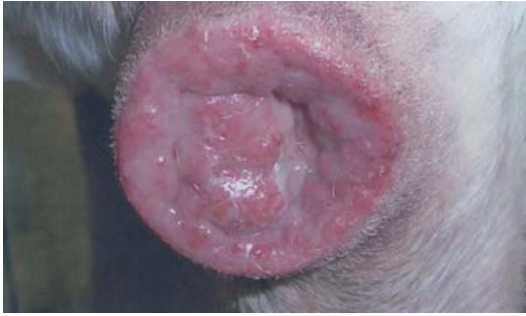In all the neoplasm I have handled I have spread the Neoplasene salve (a/k/a Sarcoma Salve #1, a/k/a Buck Mountain Black Salve) thin with a tongue depressor or gloved finger. In a few cases the salve has been reapplied in twenty-four to forty-eight hours. More time between applications seems to work just as well.

Case #1: Ali is a seven year old spayed female yellow Labrador Retriever presented on December 9, 2004 with a six centimeter spherical mass on her front left leg. The mass was removed on December 12, 2004. The skin over the lump appeared normal. Twenty cubic centimeters of blood was removed with a syringe. A hard mass palpated in the lesion. Surgical removal was accomplished. Histopathology reported that the mass was a spindle cell tumor.

Ali was fitted with an E-collar and destroyed it and broke open the sutures. The tumor returned aggressively and within seven days had regrown to nearly the size at surgical removal (figure 28).

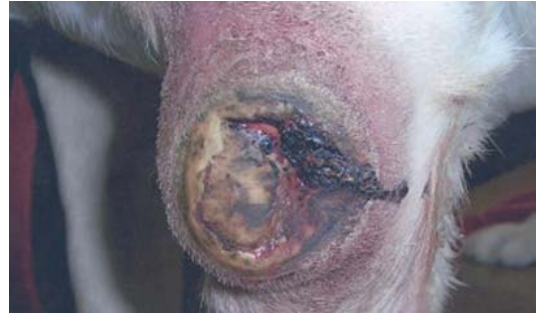Neoplasene was applied and the leg bandaged. At eighteen, twenty-five and thirty-seven hours the Neoplasene was reapplied. At sixty-four hours (i.e. two and one-half days) a large plug of necrotic tissue fell out of the inflamed area. The area in and around the tumor bed was inflamed and showed signs of healing at the end of seven days, but a ridge of granulation tissue looked suspicious and was retreated. The ridge sloughed and the area continued to heal. After initial treatments which were bandaged for about twenty-four hours each, the patient was allowed to remove devitalized tissue with lingual abrasion. After fourteen months, the area that had tumor tissue appears normal and is hair covered.

12/21/04



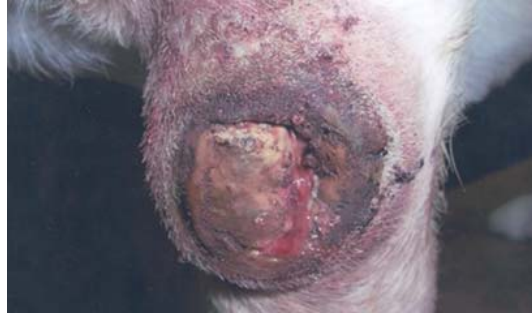Seven days post surgery

12/22/04



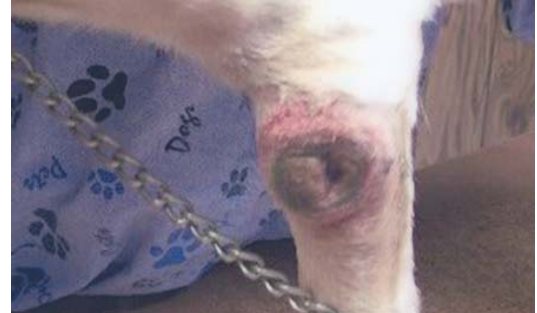18 hours later

12/22/04



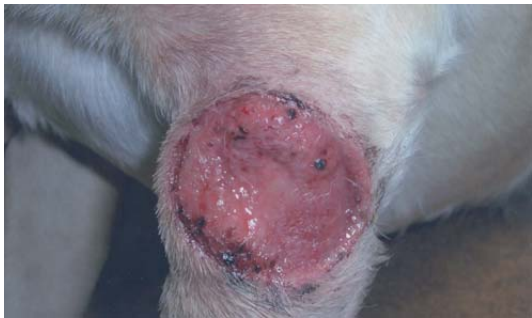7 hours later

12/24/04



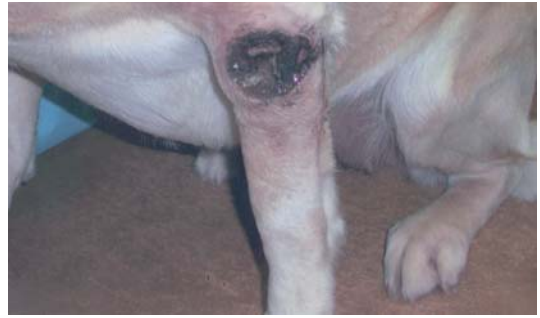inflamed and sore

12/28/04

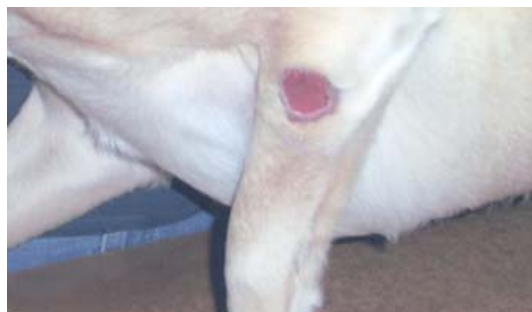

Sloughed off

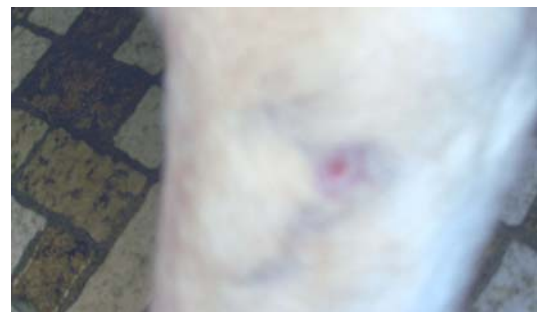12/28/04



The end is near



Ali healing



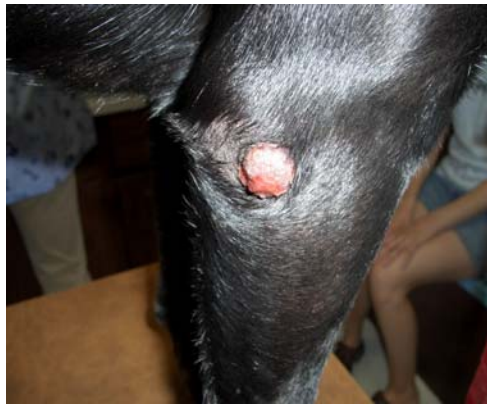The end

**Ali - Spindle Cell Carcinoma Treatment Photo Chronology
Figure 28**

Case #2:

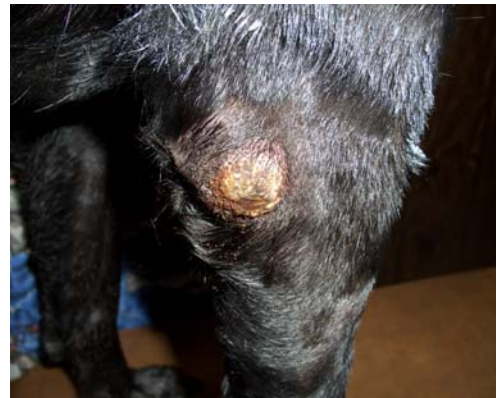
One application with Neoplasene was enough. Katie a ten year old female seventy-two pound black Labrador Retriever presented with what looked like Furunculosis. The condition was unresponsive to cortisone and antibiotics (figure). Neoplasene was applied topically for nine hours resulting in apoptosis and attendant inflammation due to the awakening of the immune system (figure 29 a, b).

Forty-eight hours (i.e. two days) later the tumor fell off (figure 29 c). The owner reports that the area healed over without a scar. Wow!



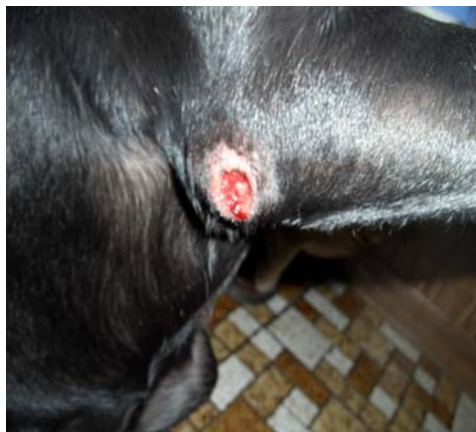Day 1 Neoplasene salve applied

-a-



Day 1 nine hours later

-b-



Two days after treatment tumor fell off

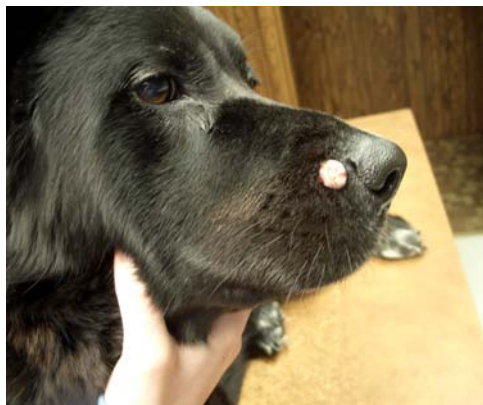
-c-

Katie - No Biopsy Tumor Treatment Photo Chronology

Figure 29

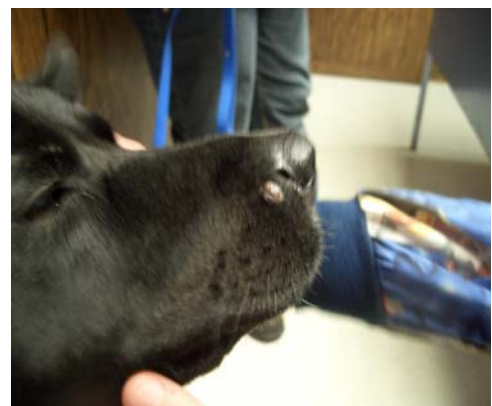Case #3:

Two applications of three and one-half and three minutes each did the job. Max, a two year old neutered male Akita mix was presented with a lump on his nose. The lump was oval shaped about one centimeter in diameter. Cephalixin treatment was started. In ten days the lump was growing. Neoplasene was applied and the mouth held shut for three and one-half minutes so patient would not lick the lump treatment area. The salve was then wiped off. Day seventeen, seven days after first application the lump was smaller (figure 30 b). Neoplasene salve was applied and wiped clean after the three minutes. On day twenty-nine, nineteen days after the first application and twelve days after the second and last application the lump was gone and a white flat scar appeared (figure 30 c). One month later, the owner reported the scar is gone and hair is growing where the lump used to be.



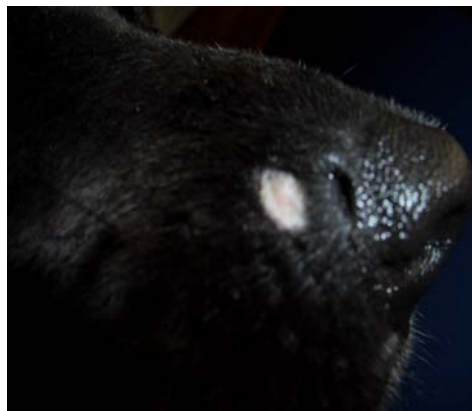Neoplasene salve applied

-a-



One week later salve reapplied

-b-



Max - Unidentified Lump Treatment Photo Chronology

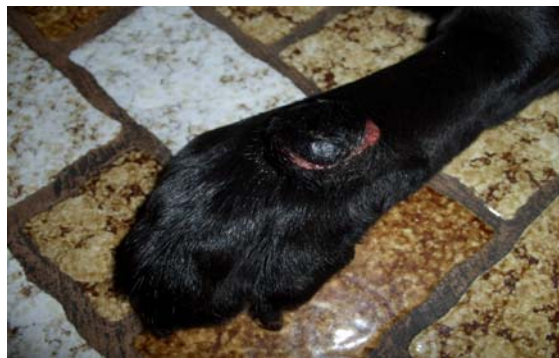-c-

Figure 30

Case #4:

An old dog required only one treatment. Abby a ten year plus old spayed female Labrador Retriever mix breed presented with a growth on the dorsal surface of the left front foot. The tumor was moveable, fluid filled and deflated somewhat.

Neoplasene was applied and two days later the tumor was circumscribed and necrotic (figure). On the third day the tumor separated. Healing ensued and normal tissue and hair covers the area (figure).



**Abby - Unidentified Growth Shown After One Treatment And Healing
Photo Chronology**

Figure 31

CASE HISTORIES

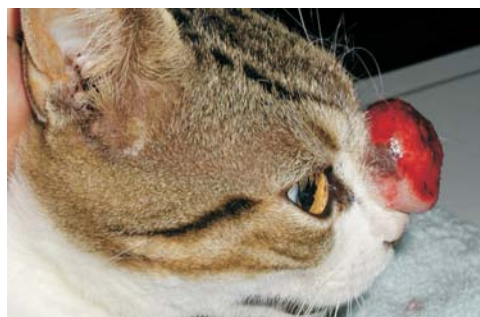Dale A. Magnusson, DVM
Magnusson Veterinary Clinic
Hudson, WI

Case #1: This case involved a feral cat with a tumor covering the bridge of its nose. Duration of the condition was unknown.

Neoplasene a/k/a Sarcoma Salve #1 was applied on days one, two and four for twelve hours. After the twelve hours the salve was cleaned off with hydrogen peroxide and Wound Balm was applied. Because the cat was fractious, sedation was required for each treatment. After three treatments, the tumor was kept protected with Wound Balm through day four. The tumor began to separate from the normal adjacent tissue by day six and fell off on day ten.

Once the tumor fell off, we were able to treat the wound daily with Wound Balm without sedation for almost a week until the cat decided he was done cooperating. At that point he was discharged. Skin margins were evident migrating in at that time. Treatment at home did not continue because of his fractiousness.

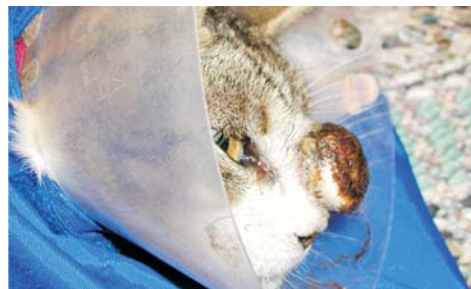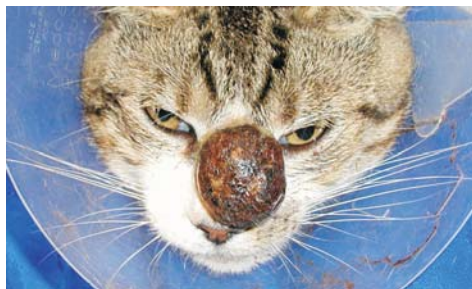Histopath was not performed on this tumor.



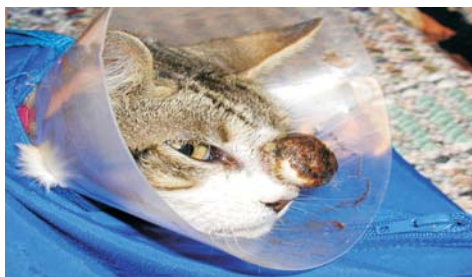Day one prior to treatment

Rudolph - The Fractious Feral Feline Treatment Photo Chronology

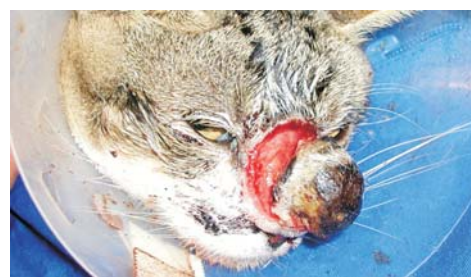Figure 32



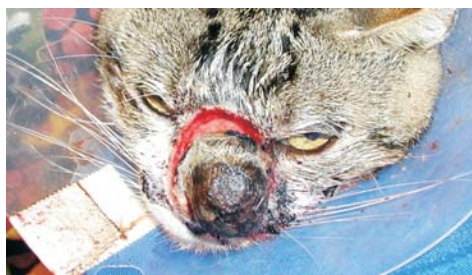Day two of treatment



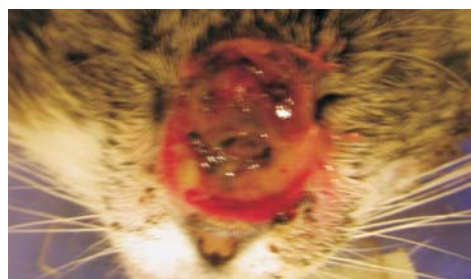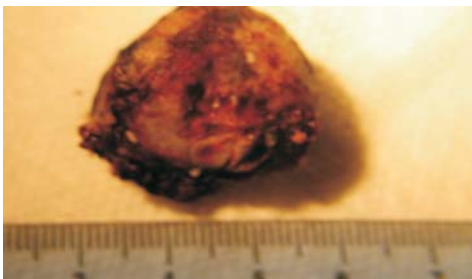
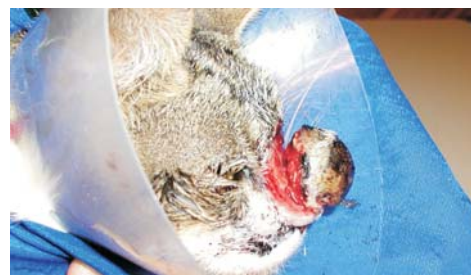Day four of treatment



Day six of treatment



Day six of treatment



Day 10 of treatment. Nasal cartilage remains intact.

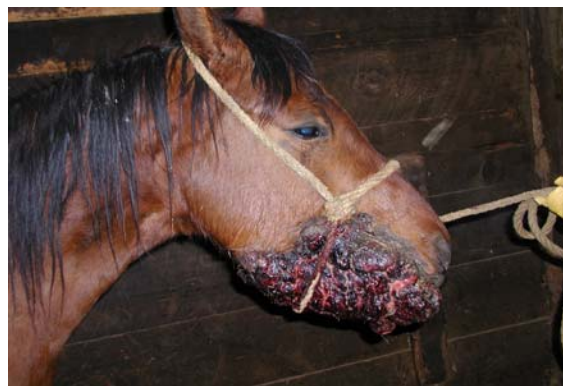
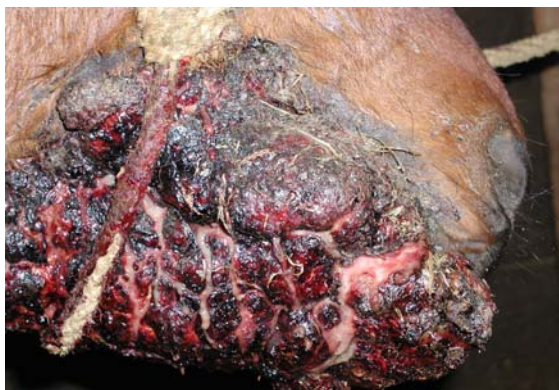
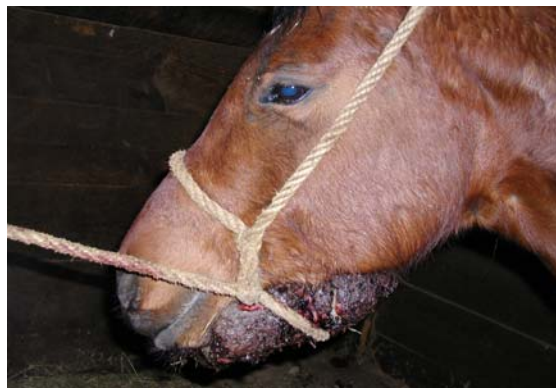
Eight months from start of treatment.

**Rudolph - The Fractious Feral Feline Treatment Photo Chronology
Figure 33**

Case #2: A three year old Quarter horse mare was first presented for treatment of oral tumors in February of 2002. She had three tumors at or near the commissures of the mouth. They were approximately four centimeters in diameter. Treatments were as follows:

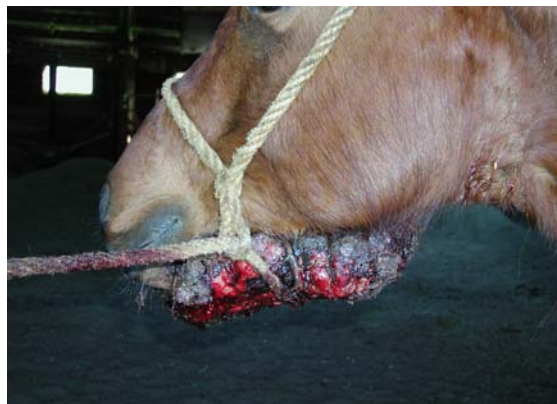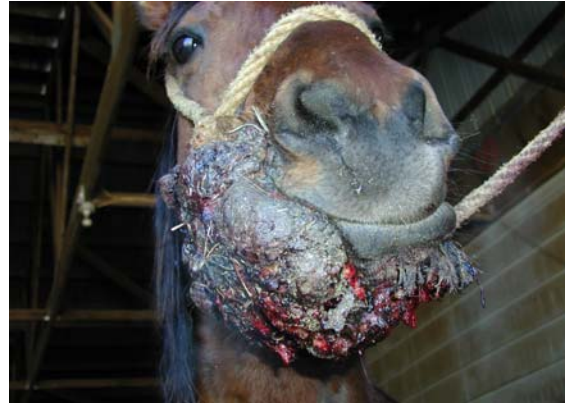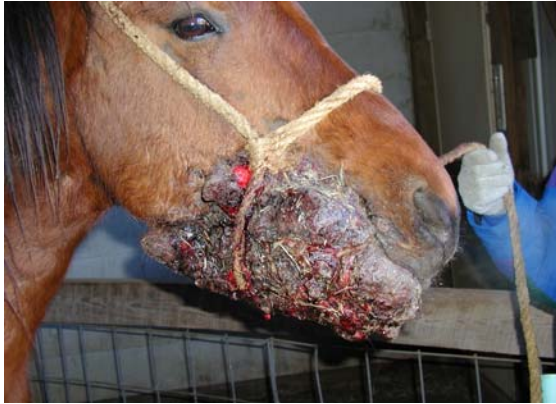- 1) We attempted laser removal that February and again in April 2002. The tumors recurred after both treatments.
- 2) Five Fluorouracil injections were next attempted. Four treatments were administered at one week intervals, starting in September of 2002, with no apparent effect.
- 3) Oral treatment with Animin was initiated in November 2002 and was used for approximately two months with no perceived benefit. Laser removal was again performed in April 2003. The tumors were still manageable at this time, but the growth was increasing.
- 4) Neoplasene a/k/a Sarcoma Salve #1 was applied starting in July of 2003. At this time the mass was extending over the exterior of the right jaw approximately twelve centimeters in diameter. The mare was very resistant to treatment as it seemed to be painful.
- 5) Laser removal was again performed. It was not possible to remove all of the mass as it was both inside and outside the mouth with extensive boundaries.
- 6) And now we get serious. In February 2006 we treated the mare with 1500 milligrams of NeoplaseneX with saline intravenously twice daily for three days. No adverse effects were noted. The tumor was then injected with approximately 15000 milligrams of NeoplaseneX on February 25, 2006 and again on March 7, 2006. Oral treatment with 1500 milligrams b.i.d. of Neoplasene was also instituted on February 25, 2006. At the time of the second injection an extensive amount of necrosis of the tumor was evident. On March 14, 2006, about half of the tumor had fallen away. The tumor was again injected with NeoplaseneX with methyl sulfoxide. It has been two weeks since the last injection. The tumor continues to regress, but progress seems to have slowed. I believe that we need to continue with weekly injections along with the twice daily oral dosing.



Photographs from 2/07/06 prior to the first I.V. NeoplaseneX injection.

Quarter Horse Mare - Oral Tumors Treatment Photo Chronology

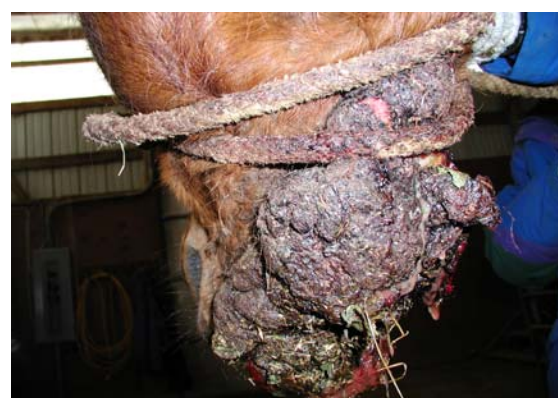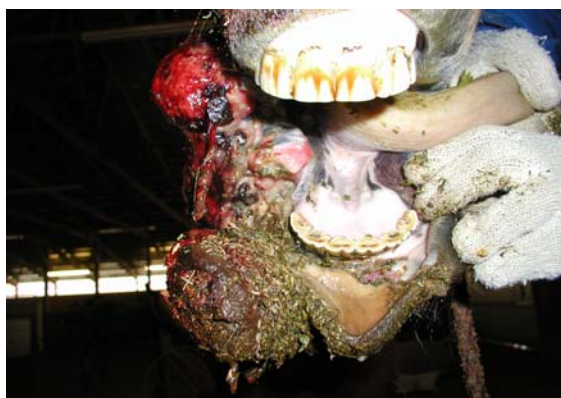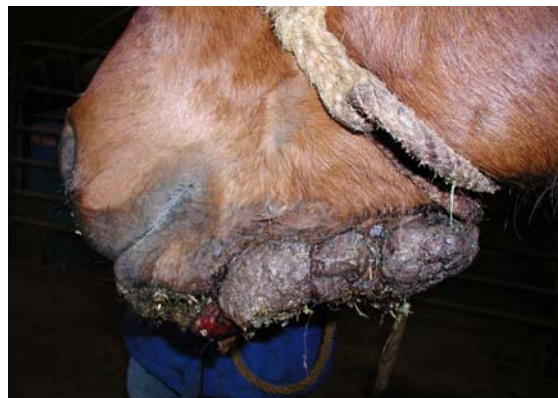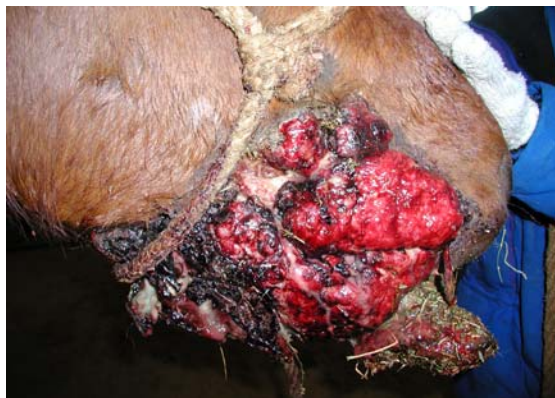Figure 34



Photos from 2/25/06, time of first injection of tumor mass with NeoplaseneX

Quarter Horse Mare – Oral Tumors Treatment Photo Chronology

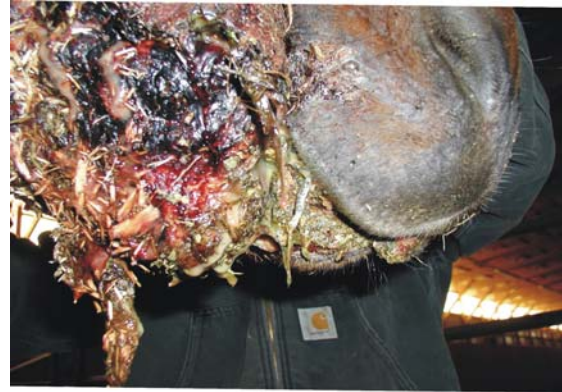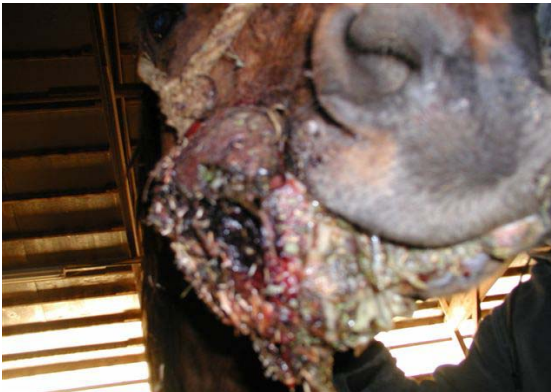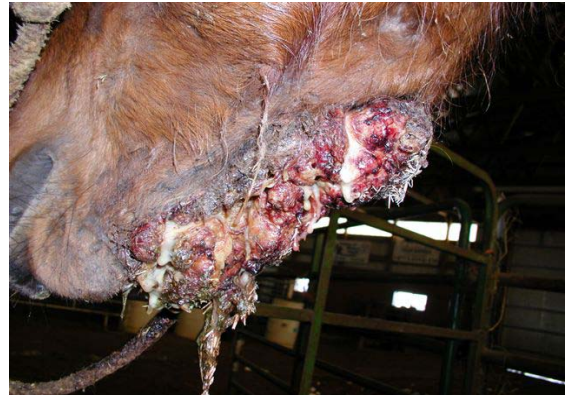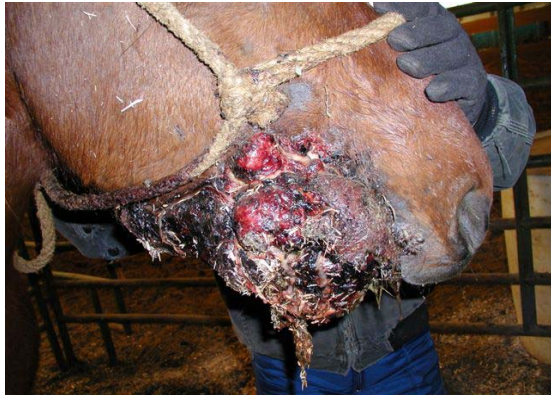Figure 35



Photographs from 3/07/06. Necrosis becoming evident. Time of second injection of tumor.

Quarter Horse Mare - Oral Tumors Treatment Photo Chronology

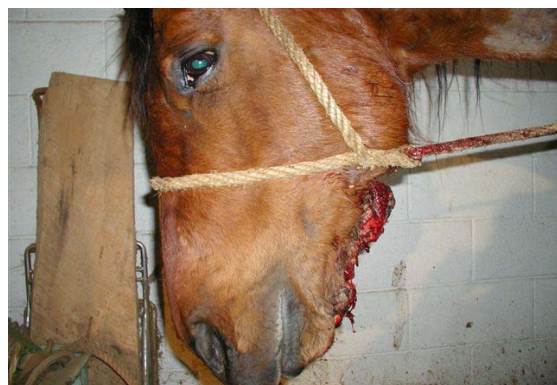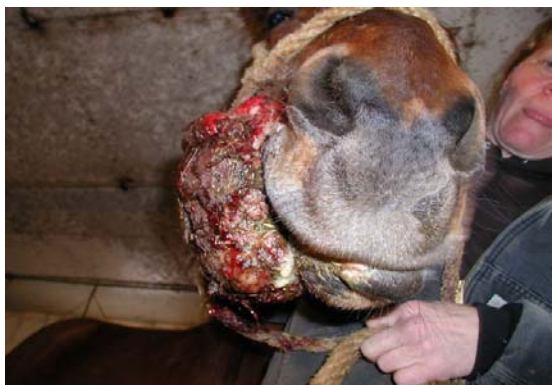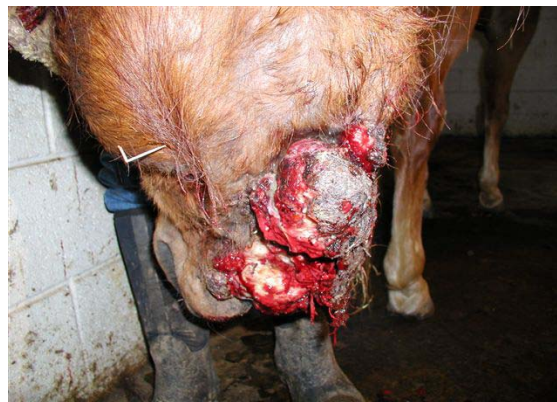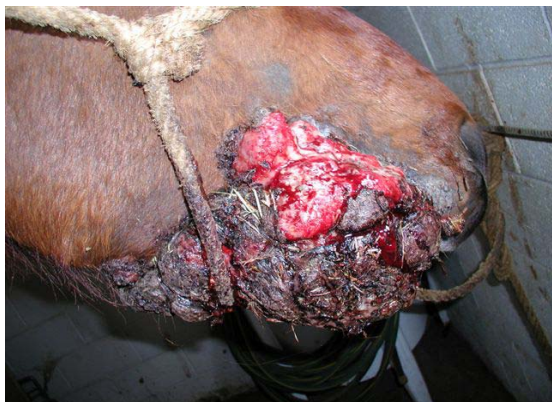Figure 36



Day 35 of Treatment

Quarter Horse Mare - Oral Tumors Treatment Photo Chronology

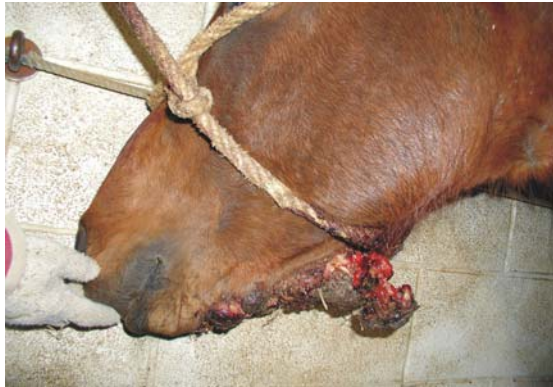Figure 37



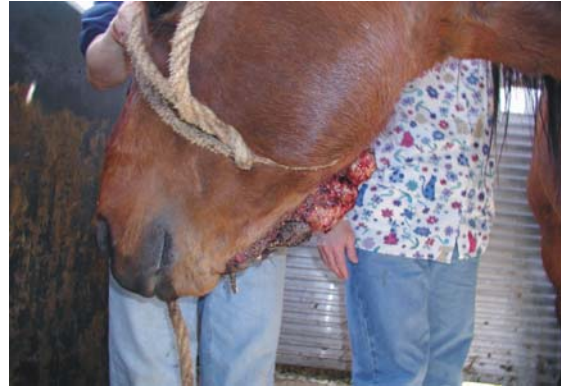Day 42 of treatment. Mare continues on oral Neoplasene. Treated today with injection of NeoplaseneX with DMSO. It has been two weeks since last injection.

Quarter Horse Mare - Oral Tumors Treatment Photo Chronology

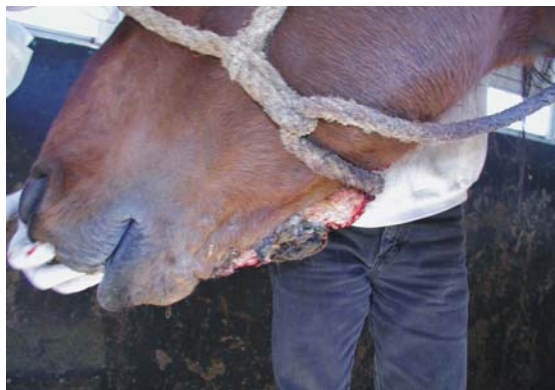Figure 38



Day 57 of Treatment



Day 64 of Treatment



Day 64 of Treatment



Day 74 of Treatment

Quarter Horse Mare - Oral Tumors Treatment Photo Chronology

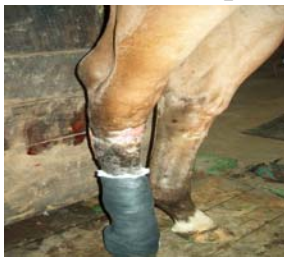Figure 39

CASE HISTORY

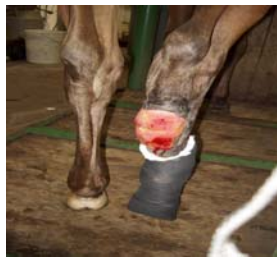Andrew A. Peterson, DVM
Enderlin Veterinary Clinic, PC
Enderlin, ND

Case #1: Dollar, a one year, two month old quarter horse gelding had a smooth wire wrapped around his right rear leg. There were wounds on the front and back of the metatarsal. The front wound was deep and down to the bone. While the back was larger in length, seven centimeters by fifteen centimeters, and had missing skin. The treatment was Cursorb zinc wound dressing placed on both the front and back wounds. The owner was instructed to change the bandage daily and to use derma-cleanse ointment on the wound.

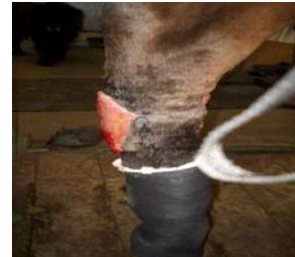On August 13, 2005, 9:00 am, the gelding's wounds appeared to be healing. The front wound had contracted down to a two centimeters by four centimeters wound that is even with the skin. The back wound is seven centimeters by fifteen centimeters with two centimeters proud flesh above the wound edges. Neoplasene a/k/a Sarcoma Salve #1 was placed on the top half of the back wound and covered with Buck Mountain Wound Balm wrapped with gauze. At 9:00 pm, the gauze was removed and replaced with Neoplasene covering the entire proud flesh wound. Buck Mountain Wound Balm was placed on a diaper positioned over the wound and secured with Vet-rap.



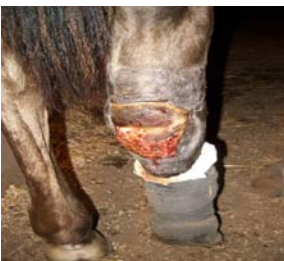Front view 8/13/05



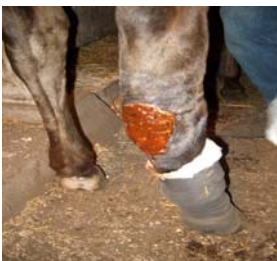Back view 8/13/05



Side view 8/13/05



8/13/05 at 11:40 pm

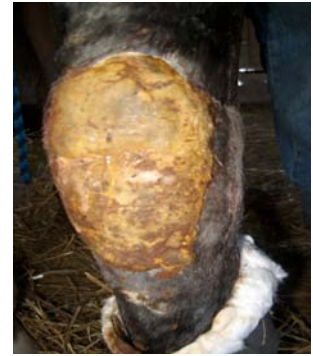
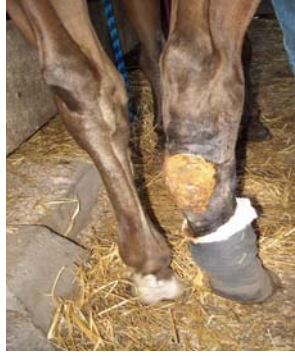
Neoplasene treatment

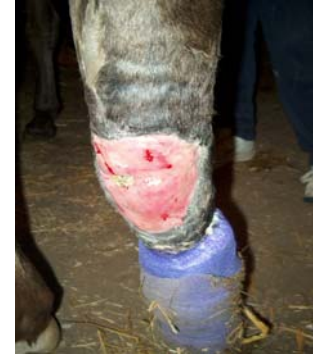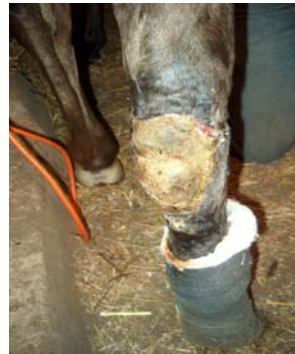Dollar - Proud Flesh Treatment Photo Chronology

Figure 40

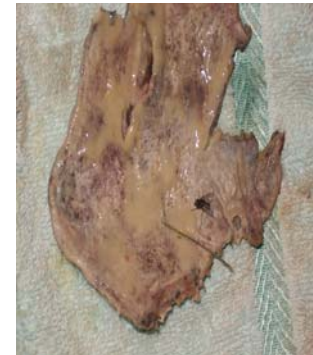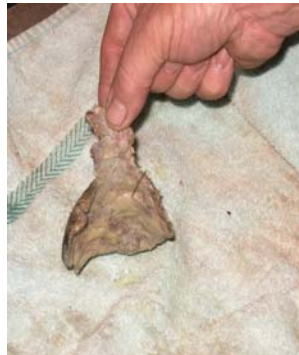August 14, 2005, 8:04 am, wound was cleaned and rinsed with Hydrogen peroxide. Buck Mountain Wound Balm was applied again with a diaper as the bandage and secured with Vet-rap. The color of the wound was a dark brown.



August 15, 2005, 9:30 pm, the bandage was removed. The lateral surface of the proud flesh started to slough off. The wound was re-wrapped with another application of Buck Mountain Wound Balm.



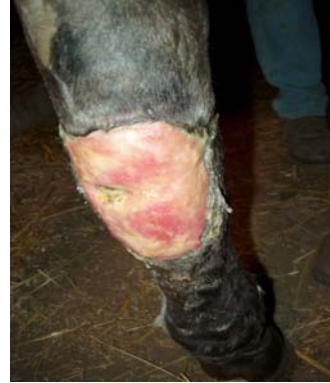August 16, 2005, 10:00 pm, the proud flesh came off the wound in one large mass. The leg was wrapped again with Buck Mountain Wound Balm. The proud flesh decreased to 1/2 to 3/4 of its original thickness.



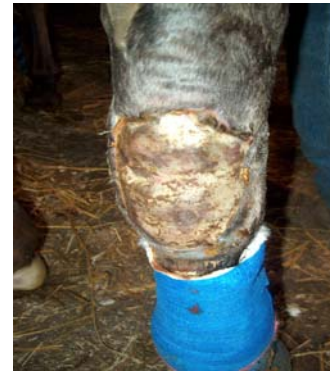Dollar - Proud Flesh Treatment Photo Chronology

Figure 41

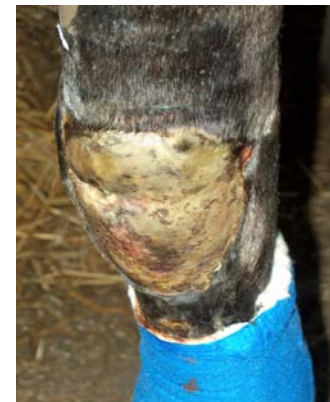August 17, 2005, 10:30 pm, the wound was moist and was covered with a white coating. There was a small hole in the medial area that was secreting a white liquid. The wound was treated with Buck Mountain Wound Balm and rewrapped.



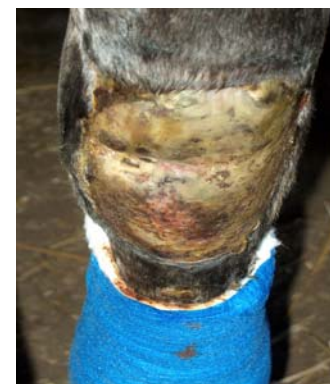August 18, 2005, 10:30 am, Neoplasene a/k/a Sarcoma Salve #1 was placed directly on the wound. Buck Mountain Wound Balm was placed on the diaper and wrapped around the wound.



August 19, 2005, 10:10 am, changed dressing and rewrapped with Buck Mountain Wound Balm.



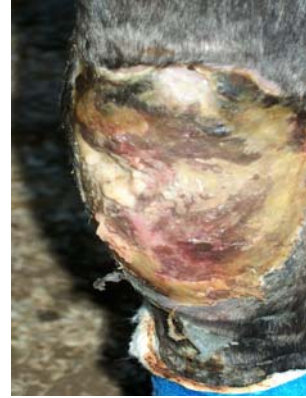August 20, 2005, 9:45 am, rewrapped with Buck Mountain Wound Balm.



Dollar - Proud Flesh Treatment Photo Chronology
Figure 42

August 21, 2005, 8:45 am, re-wrapped with Buck Mountain Wound Balm.

August 22, 2005, 7:07 am, re-wrapped with Buck Mountain Wound Balm.



August 24, 2005, 12:30 pm, proud flesh came off as a thick exudate rather than one thick piece.

August 26, 2005, 12:50 pm, the wound was at skin level. It was then sprinkled with yarrow powder a/k/a Buck Mountain Wound Aid. Buck Mountain Wound Balm was applied to the top of the wound without a dressing but did not adhere to the wound well.

August 27th, 28th, 29th and 30th, the wound was sprinkled with Wound Aid. The horse was then (Aug. 30th) turned out to pasture.

Dollar - Proud Flesh Treatment Photo Chronology

Figure 43

CASE HISTORY

Margo R. Roman, DVM
MASH Main St Animal Services of Hopkinton
Hopkinton, MA

Coco Campbell an eleven year old Shep/Chow Cross Spayed female presented to MASH Main St Animal Services of Hopkinton on April 1, 2004 with a mass on right foreleg. It appears to be a nerve sheath sarcoma. No biopsy was done. A recommendation of surgical removal was offered, others had recommended amputation. Coco was started on Hoxsey, shark cartilage, Nutrigest, Mash Mix (Vit C, Glucosamine, Vit E, Dimethyglycine DMG, Prozyme, Alfalfa, organic Spirulina), Resources Cancer Options (Medicinal Mushrooms) RX Vitamins Ultra FA Double Dosage, LM 1 to LM2 Thuja four succussions.

Continued support of this mass that grew slowly until September 12, 2005 was provided at which time an ulcer started on the outside surface. The owner had declined surgery because of the dog's age. She was informed about the choice of Neoplasene application on September 22, 2005 when initial photo was taken.

Neoplasene was applied after some small twenty-five gauge needle pricking was done on a five eighths inch grid to the mass without anesthesia. A thin layer of Neoplasene was applied to the mass. The area was shaved around the lesion and calendula ointment was applied around on the healthy tissue. A Telfa pad and bandage was applied. Subcutaneous ozonated saline was given. The client was instructed on the care of the lesion and on how to reapply the salve in forty-eight hours. See Pictures.

Continued applications per owner and technician ensued with large chunks of the tumor falling off during routine bandage changes. Coco walked and ate normally and was kept away from lesion with a bandage and a Bonifido collar.

On September 29, 2005 the lesion starts to break down. By October 1, 2005 the tissue was separating. On October 3, 2005 a large chunk lifts off. Treatment continued from October 3, 2005 to October 7, 2005 and small amounts of the tumor were being removed. Ventral dripping of Neoplasene to distal part of the forearm caused a sloughing of tissue that may have been affected by the cancer on October 8, 2005.

By October 9, 2005-October 13, 2005 continued shedding of the distal area occurred and between October 15 and October 18, 2005 granulation was occurring. Yarrow powder a/k/a Buck Mountain Wound Aid was added to Wound Balm. The October 18, 2005 photo indicates the removal of all the mass and a return to normal tissue. From October 20, 2005 to November 16, 2005 healing with total skin epithelialization of the leg occurred.

Pro and Cons

Pros

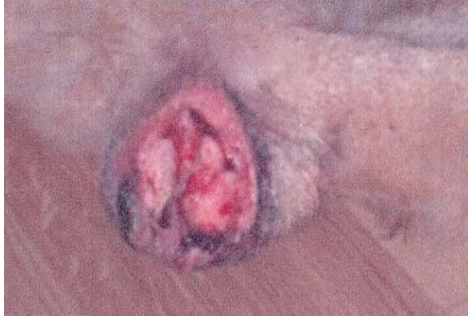The use of Neoplasene avoids lengthy anesthesia and results in the removal of cancerous tissue around other structure.

Cons

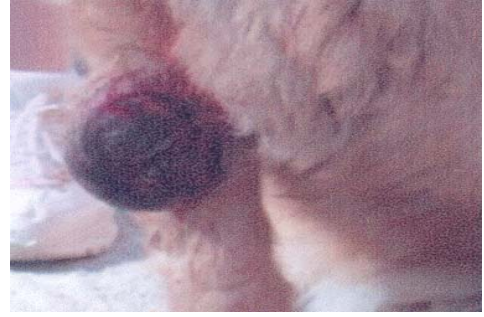Must have client compliance as wound may need multiple bandage changes and can be rather unsightly.

Things to prepare for:

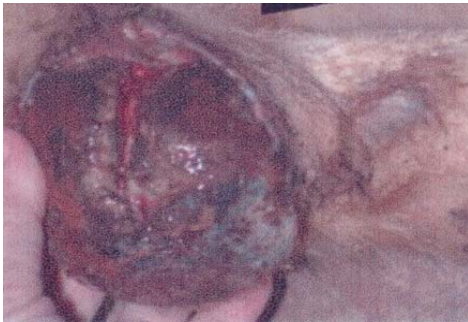- Make sure the growth has a widely shaven area as there is drainage and if skin is ventral or distal the salve and exudates can cause irritation to lower tissue.
- Use only a thin coating of salve on the lesion so that it doesn't slide and drip off.
- Use a liberal amount of Calendula or non-petroleum ointment to coat the surrounding tissue.
- Don't allow the tissue to dry out as the dying tissue gets dried out and will adhere to the deeper tissue and will bleed if you try to remove the dried tissue.
- Be prepared that there will be swelling distal to the location on the limb.
- Using ozone either subcutaneously with saline or to bag the leg will help in preventing any secondary infection.
- Don't forget to stop any antiangiogenic supplements like shark cartilage as it slows the healing.



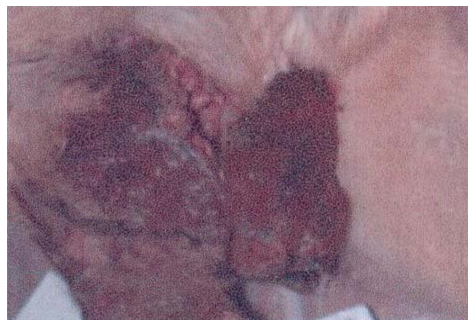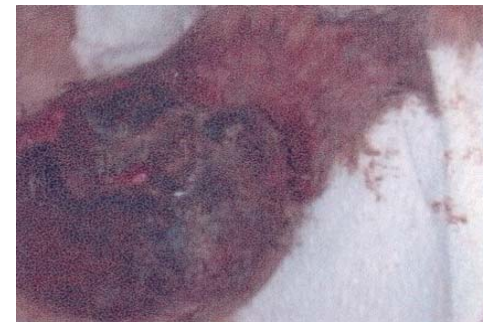
9/22/05



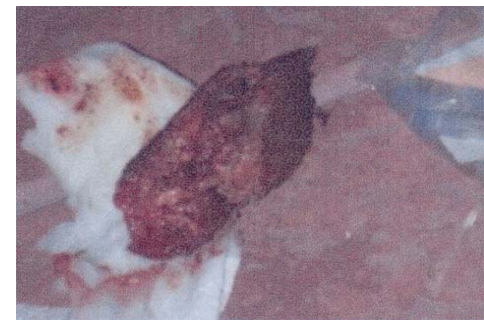9/22/05



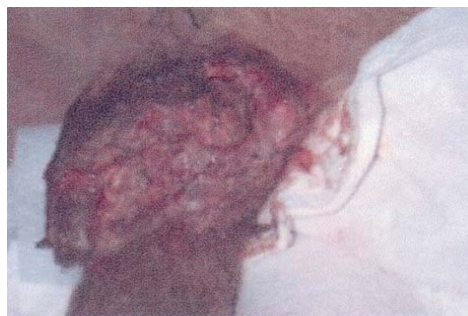10/1/05



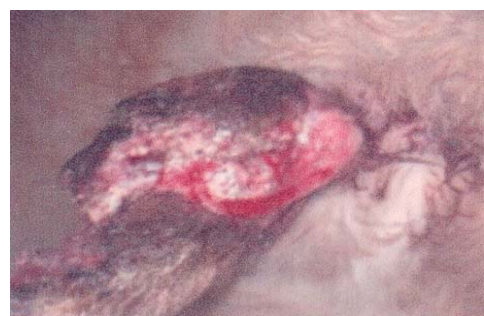10/3/05



10/3/05



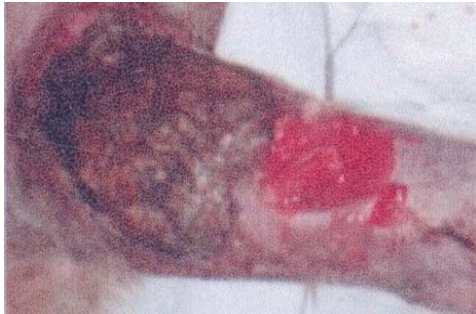10/3/05



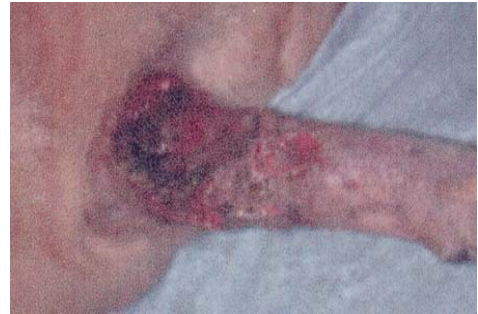10/7/05

Coco - Bout With Cancer Treatment Photo Chronology

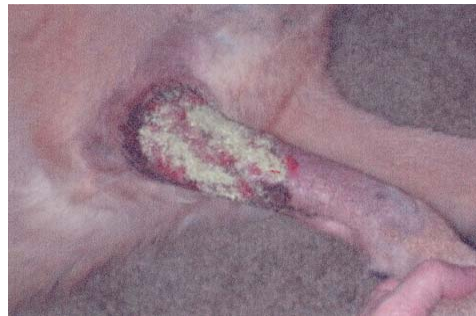Figure 44



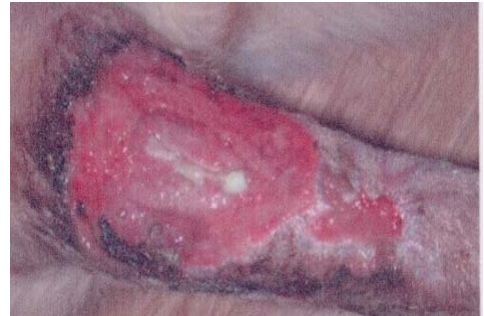10/8/05



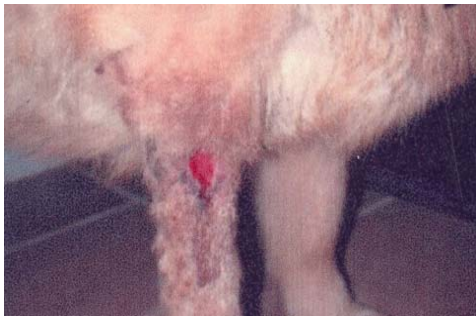10/9/05



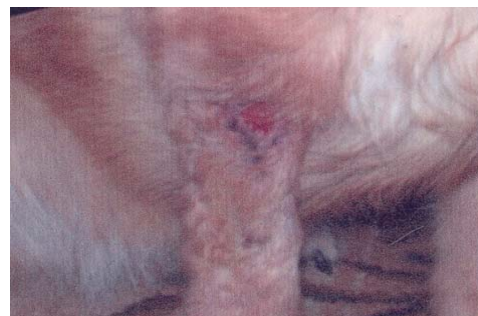10/13/05



10/15/05 - 10/18/05



10/20/05



11/16/05

Coco - Bout With Cancer Treatment Photo Chronology

Figure 45

CASE HISTORY

Nancy N. Scanlan, DVM
Sherman Oaks, CA

ORAL TUMORS

Neoplasene, a/k/a Sarcoma Salve #1 can be used for oral tumors, also. It can be curative if the tumor is small enough, or palliative, if the tumor is extensive. Used in cats for squamous cell carcinoma, it can extend comfortable life to more than a year, compared with one to four months usually seen. In dogs, with low-grade SCC in the rostral part of the mouth, it can be curative, avoiding a mandibulectomy.

Treatment of oral tumors with Neoplasene is a little different, since saliva and the action of the tongue wash the salve away. Treatment works best if the salve can be applied every two to three days. If done more often, ulceration often interferes with eating and drinking. Only a thin layer is needed. If the tumor is eroded, this will initially be painful, then relief will be felt. Cats will often stop drooling and start eating within a day to two days after application.. If the tumor is primarily within the tongue, swab the salve on the entire lower surface of the tongue. After two or three initial treatments, to make sure it is responding and to show the owners the technique, the salve can be dispensed for the owners to apply it. Progress should be checked every two to four weeks.

For animals who will not allow treatment in this fashion, or who have tumors in the back of the mouth, a twenty to thirty minute application while they are anesthetized can have an effect. These are more likely to return, requiring further twenty minute treatments.

If too much is used, or if the salve must be applied at the back of the throat, vomiting occurs, which is unpleasant for the patient. This can become reflex vomiting at the sight of the jar or of the veterinarian. It is important to start early, while the tumor is still small: if it is too large, extensive application can cause mass necrosis with resulting severe pain and secondary infection. Tumors with extensive bone involvement do not respond well—the surface often improves, but the bony lesions remain. Tumors with beginning bone involvement can respond well. Squamous cell carcinoma responds better than malignant melanoma, in both dogs and cats.

FIBROSARCOMA IN THE CAT

I don't have any primary cases of fibrosarcoma—everyone so far who has come to me has had two or more surgeries and sometimes radiation. Most of the time their tumors are far too big to respond well. There are two cat patients who are interesting:

1 cat had radiation therapy and surgery three times, the last time included removing the tops of the scapulae. Two one centimeter diameter tumors had recurred dorsally, and an MRI showed they actually extended all the way down the right side to the axilla. I applied the salve to the top, and the entire side of the cat opened up, all the way down to the axilla. The first time, we got remission for six months, whereas it had recurred within two months of surgery. Each time it recurred, salve was applied, but the pattern was the same as for other treatments: it recurred faster and faster and at the end it grew faster than the salve could keep up. The cat was on other supplements, including Hoxsey, at the time.

I have just started with a second cat, two prior surgeries, recurred faster after the second time, with two, three millimeter lesions just beginning dorsally under the skin, not attached to the skin. Treated by pricking the skin and applying Neoplasene. One opened up, the other disappeared. Problem is, the owner leaves the country in a week and will be gone for five weeks. We'll see how this goes.

CUTANEOUS HEMANGIOSARCOMA IN THE CAT

In the cat, these are locally malignant but rarely metastasize. Recommendation was for amputation (it was on the carpus). Visually, the salve took the whole thing away, punched a perfectly round hole in the skin, could see all sub q and tendons, but it grew back rapidly. Tried it several times, longer times, left it on for days at the end, but it acted the same. Ended up with amputation.